



# MLA AKT Practice Paper

## Part 1

The MS AKT Exam Board has put together a 200-item practice exam (2 x 100 item papers) to help medical students prepare for the UK Medical School Applied Knowledge Test (MS AKT). Blueprinted to the GMC Content Map this exam has been designed to reflect the style and type of question that students will encounter when sitting the MS AKT.

The practice exam comes with and without the answer options.

We would like to recognise the contribution of medical schools, and members of the AKT Exam Board in particular, in producing this exam which we hope students will find a valuable resource.

Please note this practice exam is reviewed on an annual basis and updated accordingly. Should you have any questions about the clinical content of the practice exam please speak to the Assessment Lead in your school in the first instance.

**Any redistribution or reproduction of part or all of the contents in any form is prohibited other than for personal, educational and non-commercial use.**



1. A 24 year old man has poor urine flow and takes a very long time to empty his bladder. He has no other urinary symptoms. He has been well previously apart from one episode of non-gonococcal urethritis 1 year ago.

What is the most likely diagnosis?

- A. Overactive bladder
- B. Neurogenic bladder
- C. Phimosi
- D. Prostatic hypertrophy
- E. Urethral stricture

2. A 67 year old man is found to have an ejection systolic murmur. He is otherwise well.

His pulse is 72 bpm and BP 128/84 mmHg. His chest is clear.

Investigations:

ECG shows sinus rhythm.

Echocardiography shows aortic stenosis, valve gradient 50 mmHg. Left ventricular (LV) diastolic dysfunction, LV ejection fraction 45% (>55).

What is the most appropriate management?

- A. Clinical review and echocardiography in 6 months
- B. Reassure and discharge
- C. Refer for aortic valve replacement
- D. Start bisoprolol fumarate and advise review if symptomatic
- E. Start lisinopril and advise review if symptomatic



3. A 27 year old woman has muscle weakness which is worse on exercise. When asked to count from one to 100 her voice progressively becomes weaker. She has bilateral ptosis.

Which pathophysiological process is most likely to be responsible for this disorder?

- A. Autoimmunity
- B. Genetic disorder
- C. Infarction
- D. Malignancy
- E. Meningeal infection

4. A 46 year old man has pain in his left leg and tingling in his left big toe. He developed severe lower back pain 1 week ago and he is unable to walk on his left heel.

There is loss of pinprick perception over the left great toe.

Which nerve root is the most likely to have been affected?

- A. L1
- B. L3
- C. L5
- D. S1
- E. S2



**5.** A 52 year old man has three days of severe epigastric pain, radiating to his back, but no chest pain. He has vomited several times. He was previously well. He drinks approximately 60 units of alcohol a week and smokes 20 cigarettes per day.

There is epigastric tenderness but his abdomen is not distended, and bowel sounds are present.

Which test would confirm the most likely diagnosis?

- A.** Abdominal X-ray
- B.** Gastroduodenoscopy
- C.** Serum alkaline phosphatase concentration
- D.** Serum amylase concentration
- E.** Ultrasound scan of abdomen

**6.** A 24 year old man attends the emergency department after 2 days of vomiting. He has type 1 diabetes. He is drowsy but maintaining his airway.

His pulse is 100 bpm, BP 90/60 mmHg, respiratory rate 30 breaths per minute and oxygen saturation 96% breathing air.

Investigations:

Blood capillary glucose	32 mmol/L	
Blood capillary ketones	6.2 mmol/L	(<0.6)
Venous pH	7.15	(7.35–7.45)

What is the most appropriate initial treatment?

- A.** Intravenous 0.9% sodium chloride
- B.** Intravenous 1.26% sodium bicarbonate
- C.** Intravenous antibiotics
- D.** Intravenous insulin
- E.** Subcutaneous insulin



7. A 24 year old woman has diarrhoea. She is HIV positive and has been working in Namibia.

Investigation:

Faeces microscopy (following modified Ziehl–Neelsen stain): protozoa

What is the most likely causative organism?

- A. Acanthamoeba
- B. Cryptosporidium parvum
- C. Entamoeba coli
- D. Plasmodium falciparum
- E. Schistosoma mansoni

8. A 67 year old man has difficulty chewing and speaking. He underwent carotid surgery 2 days ago.

His tongue deviates to the right when he is asked to protrude it.

Which nerve has been damaged?

- A. Left glossopharyngeal nerve
- B. Left hypoglossal nerve
- C. Left vagus nerve
- D. Right glossopharyngeal nerve
- E. Right hypoglossal nerve



**9.** An 18 year old woman has had 3 years of intermittent zig-zagging and flashing lights in both eyes associated with headache. These episodes occur 2-3 times per month and last approximately half an hour. The symptoms are associated with nausea and vomiting. Her vision is affected at the time of each episode but returns to normal afterwards.

What is the most likely diagnosis?

- A.** Acute glaucoma
- B.** Migraine
- C.** Occipital lobe epilepsy
- D.** Retinal detachment
- E.** Tension-type headache

**10.** A 75 year old man has had 3 days of intermittent headaches, blurred vision and vomiting. For the past 24 hours he has had a severe left sided headache and eye pain, accompanied by blurred vision and vomiting. His left eye is red and the left pupil is dilated.

What investigation is most likely to confirm the diagnosis?

- A.** CT scan of head
- B.** Erythrocyte sedimentation rate
- C.** Fluorescein staining of the cornea
- D.** Measurement of intraocular pressure
- E.** MR scan of head



**11.** A 72 year old woman has had 4 months of progressive difficulty walking. She describes numbness and tingling in her feet and has fallen on several occasions.

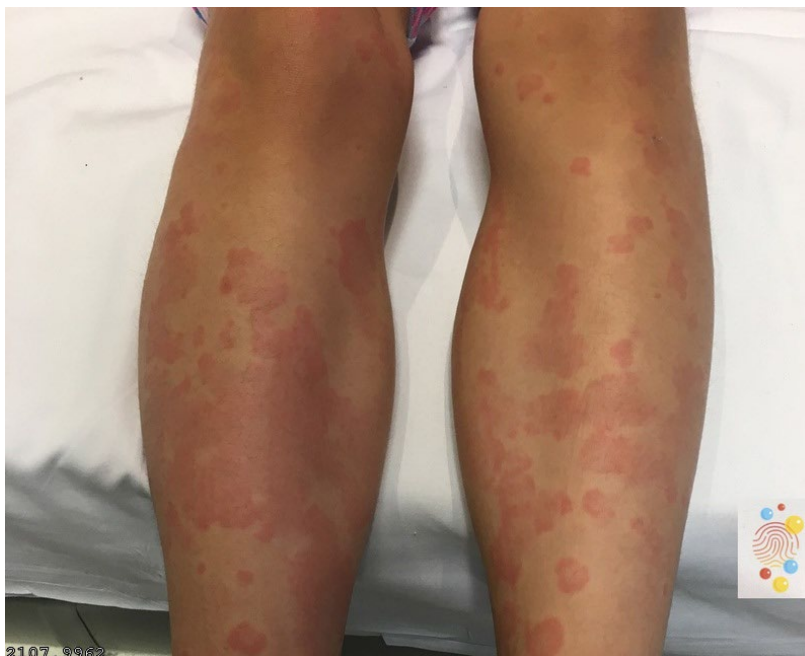She has normal tone of her lower limbs, moderate weakness of ankle dorsiflexion and plantar flexion, normal knee jerks, but absent ankle jerks and extensor plantars. Romberg test is positive. She has reduced vibration sense, and joint position sense is impaired up to the ankle joints. Temperature and pinprick sensations are normal.

What investigation is most likely to confirm the diagnosis?

- A.** HbA1C
- B.** Serum folate
- C.** Serum protein electrophoresis
- D.** Serum vitamin B12
- E.** Serum vitamin D



12. A 34 year old woman has a recurrent itchy rash which lasts for several hours before resolving (see image). She has not identified any triggers. She is systemically well. She is a firefighter and says that she does not want any treatments that may affect her level of alertness.



What is the most appropriate treatment to control her symptoms?

- A. Oral chlorphenamine maleate
- B. Oral loratadine
- C. Oral prednisolone
- D. Topical aqueous cream
- E. Topical hydrocortisone



**13.** A 29 year old woman has 2 days of marked loss of vision and acute pain in her left eye. The pain is worse when she changes her gaze direction.

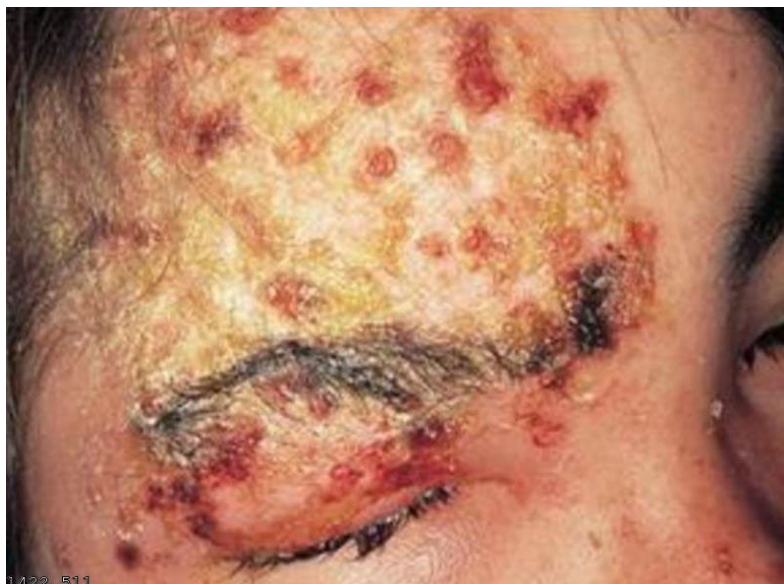Her eyes appear normal on general inspection. Her vision is 'count fingers only' in the affected eye. The swinging flashlight test shows that the left pupil dilates when a bright light is moved from the right eye to the left eye. The optic discs are normal on fundoscopy.

What is the most likely diagnosis?

- A.** Acute closed angle glaucoma
- B.** Giant cell arteritis
- C.** Idiopathic intracranial hypertension
- D.** Migraine with aura
- E.** Retrobulbar optic neuritis

- 14.** A 45 year old woman develops an intensely painful eruption around her right eye. The illness started with pain 5 days previously, followed by the appearance of a few vesicles, which has now developed into the rash (see image). She has no significant medical history.

Treatment is started.



What is the most likely long-term outcome?

- A.** Complete resolution with no sequelae
- B.** Corneal ulceration
- C.** Extensive scarring of the right temple
- D.** Partial ptosis
- E.** Reduced visual acuity



**15.** A 48 year old woman has rheumatoid arthritis. She takes regular paracetamol and has no drug allergies. She is due to commence methotrexate weekly.

What additional treatment should be prescribed?

- A.** Calcium carbonate
- B.** Folic acid
- C.** Pyridoxine hydrochloride
- D.** Thiamine
- E.** Vitamin D

**16.** A 74 year old woman has 6 months of progressive weakness of her right leg and 3 months of a similar problem on the left, resulting in several falls. She has also noticed difficulty using her hands and can no longer fasten the buttons on her clothes.

There is wasting of both legs and the hands, particularly the thenar eminences. There is fasciculation in her right quadriceps. Tone is increased in both legs, with brisk reflexes.

What is the most likely diagnosis?

- A.** Chronic inflammatory demyelinating polyneuropathy
- B.** Motor neurone disease
- C.** Multiple sclerosis
- D.** Myasthenia gravis
- E.** Polymyositis



**17.** A 61 year old man has had 2 months of ankle swelling. He has hypertension and a 30 year history of seronegative polyarthritis. His medication includes diclofenac, hydroxychloroquine sulfate, ramipril and sulfasalazine.

His BP is 156/90 mmHg. He has pitting oedema to mid thigh and signs of chronic deforming polyarthropathy in his hands, but no joint tenderness. His optic fundi show silver wiring and arteriovenous nipping. Urinalysis: protein4+, no other abnormalities.

Investigations:

Sodium	133 mmol/L	(135–146)
Potassium	5.4 mmol/L	(3.5–5.3)
Urea	9.0 mmol/L	(2.5–7.8)
Creatinine	119 µmol/L	(60–120)
Albumin	21 g/L	(35–50)
CRP	43 mg/L	(<5)

Urinary protein:creatinine ratio 1100 mg/mmol (<30)

What is the most appropriate initial treatment?

- A. Candesartan cilexetil
- B. Furosemide
- C. Indapamide
- D. Prednisolone
- E. Prednisolone and cyclophosphamide

**18.** A 75 year old woman has had 5 months of a 2 cm red plaque on her leg.

Investigation:  
Skin biopsy: Bowen disease

What is the most appropriate topical treatment?

- A. 5-fluorouracil (Efudix®) cream
- B. Betamethasone valerate (Betnovate®) cream
- C. Diclofenac (Solaraze®) gel
- D. Isotretinoin gel
- E. Salicylic acid gel



**19.** A 32 year old woman has had palpitations and hot flushes for 4 weeks. She has noticed a painless swelling in her neck over the same time and her weight has decreased by 2 kg. She gave birth 4 months ago after a normal pregnancy. She is not breastfeeding.

Her pulse is 120 bpm and BP 140/90 mmHg. She is tremulous and restless. She has a large smooth non-tender goitre.

Investigations:

Free T4	35.6 pmol/L	(9–25)
Free T3	10.8 pmol/L	(4.0–7.2)
TSH	<0.01 mU/L	(0.3–4.2)
Thyroid peroxidase antibodies	>1600 IU/L	(<50)
Thyroid stimulating antibodies	<1.0 IU/L	(<1.75)

What is the most appropriate initial treatment?

- A. Carbimazole
- B. Propranolol
- C. Propylthiouracil
- D. Thyroidectomy
- E. Thyrotropin alfa

**20.** An 80 year old man has an ulcer over the left heel and reduced mobility. He has a loss of appetite. He has type 2 diabetes mellitus and has previously had a myocardial infarction.

The ulcer is 3 cm in diameter and deeply penetrating. Sensory testing shows reduced vibration sense but normal sensation to light touch.

His Doppler ratio (ankle brachial pressure index) on the left is 0.68 and on the right is 0.98 (normal value 1.00).

What is the most likely mechanism of his ulcer?

- A. Arterial
- B. Neuropathic
- C. Nutritional
- D. Vasculitic
- E. Venous



**21.** A 73 year old man is in hospital with a chest infection. He has several episodes of confusion, anxiety and aggression, during which he attempts to leave the hospital. He is convinced he is being 'spied on' by the doctors and nurses and insists that 'cameras have been installed in my room'. These episodes alternate with periods of marked lethargy, which become more pronounced towards the evening.

His temperature is 37.8°C, pulse 100 bpm, BP 110/73 mmHg and respiratory rate 12 breaths per minute.

What is the most likely diagnosis?

- A. Alzheimer dementia
- B. Bipolar disorder
- C. Delirium
- D. Lewy body dementia
- E. Schizophrenia

**22.** A 78 year old woman is admitted to the surgical unit with a suspected vesicocolic fistula. She has hypertension, type 2 diabetes mellitus and angina. She takes amlodipine, metformin, gliclazide, simvastatin and bisoprolol.

Her serum creatinine is 120  $\mu\text{mol/L}$  (60–120).

The consultant surgeon requests a CT scan of abdomen with contrast.

Which medication should be stopped before her CT scan?

- A. Amlodipine
- B. Bisoprolol
- C. Gliclazide
- D. Metformin
- E. Simvastatin



**23.** A 50 year old man has a 3 month history of right loin pain and weight loss. For the past 20 years, he has smoked ten cigarettes per day.

His temperature is 37.4°C, pulse is 72 bpm and BP is 142/74 mmHg.

Investigations:

Haemoglobin	11.2 g/L	(130–175)
Platelets	$340 \times 10^9/L$	(150–400)
White cell count	$10.1 \times 10^9/L$	(4.0–11.0)
Urinalysis blood	3+	

What is the most likely diagnosis?

- A. Benign prostatic hypertrophy
- B. Pyelonephritis
- C. Renal calculus
- D. Renal cancer
- E. Urinary tract infection

**24.** A 74 year old man has been increasingly unwell with progressive thirst and nausea for 2 weeks. He initially described needing to pass urine more frequently than usual, but now he has not passed urine for 24 hours. He has type 2 diabetes.

He is dehydrated.

Investigations:

Sodium	149 mmol/L	(135–146)
Potassium	5.2 mmol/L	(3.5–5.3)
Chloride	101 mmol/L	(95–106)
Urea	15.4 mmol/L	(2.5–7.8)
Creatinine	208 $\mu\text{mol/L}$	(60–120)
Fasting glucose	41.7 mmol/L	(3.0–6.0)

What is the calculated serum osmolality?

- A. 206.1 mmol/L
- B. 255.2 mmol/L
- C. 312.3 mmol/L
- D. 355.1 mmol/L
- E. Impossible to calculate, more information needed



**25.** A 65 year old man receives a renal transplant. He is transferred back to the ward after four hours in recovery.

His pulse is 106 bpm regular, BP 110/70 mmHg and respiratory rate 18 breaths per minute. His chest is clear on auscultation. His urine output has been 15–20 mL per hour while in recovery. Drain output has been 120 mL since surgery.

Investigations:

Haemoglobin	90 g/L	(130–175) (preoperative level 103 g/L)
Sodium	142 mmol/L	(135–146)
Potassium	5.8 mmol/L	(3.5–5.3)
Urea	31.9 mmol/L	(2.5–7.8)
Creatinine	590 µmol/L	(60–120)

What is the next most appropriate management step?

- A. Blood transfusion
- B. Fluid challenge
- C. Furosemide
- D. Haemofiltration
- E. Insulin and dextrose infusion

**26.** A 64 year old man has developed a tremor in both arms over the last 6 months. It is worse on the right. He also reports difficulty sleeping due to restlessness.

He appears emotionally flat and has a tremor at rest that is alleviated on movement.

Which neurotransmitter is most likely to be deficient?

- A. Acetylcholine
- B. Dopamine
- C. Glycine
- D. Norepinephrine (noradrenaline)
- E. Serotonin



**27.** An 85 year old man is admitted from a nursing home with a spreading cellulitis originating from an ulcer over his right ankle.

He is mildly confused. His temperature is 39.5°C, pulse 96 bpm and BP 114/60 mmHg.

Cultures taken from the ulcer and blood have grown MRSA.

What is the most appropriate initial antibiotic treatment?

- A. Co-amoxiclav
- B. Flucloxacillin
- C. Meropenem
- D. Piperacillin with tazobactam
- E. Vancomycin

**28.** A 75 year old man is found collapsed at home and is brought to the emergency department. He has right sided weakness and reduced consciousness. He has type 2 diabetes mellitus, atrial fibrillation and hypertension. He takes warfarin.

Investigations:  
INR 4.6 (<1.4)

CT scan of the head shows a large intracranial haemorrhage.

He is given intravenous vitamin K.

What is the most appropriate next additional treatment?

- A. Cryoprecipitate
- B. Fresh frozen plasma
- C. Fibrinogen concentrate
- D. No additional treatment needed
- E. Prothrombin complex concentrate



**29.** A 76 year old woman has no energy and reports excessive tiredness for 3 weeks. She has lost 5 kg in weight over the past 3 months. She drinks 30 units of alcohol per week.

She is thin and jaundiced. Her temperature is 37.2°C. She has a palpable epigastric mass and 4 cm liver edge.

What is the most likely diagnosis?

- A. Cholangiocarcinoma
- B. Cholecystitis
- C. Cirrhosis of the liver
- D. Hepatocellular carcinoma
- E. Pancreatic adenocarcinoma

**30.** A 76 year old woman with hypertension is taking amlodipine 10 mg daily.

A 24 hour BP measurement shows a mean BP of 168/90 mmHg.

Investigations:

Sodium	135 mmol/L	(135–146)
Potassium	4.0 mmol/L	(3.5–5.3)
Urea	7 mmol/L	(2.5–7.8)
Creatinine	100 µmol/L	(60–120)
eGFR	68 mL/min/1.73 m <sup>2</sup>	(>60)

Urinary albumin : creatinine ratio 50 mg/mmol (<3.5)

Which class of antihypertensive should be added?

- A. ACE inhibitor
- B. Alpha blocker
- C. Beta blocker
- D. Loop diuretic
- E. Thiazide-like diuretic



**31.** A 70 year old man is an inpatient on the cardiology ward. He has worsening breathlessness that woke him up last night.

His pulse is 99 bpm, BP 160/100 mmHg and respiratory rate 20 breaths per minute. Auscultation of the chest reveals bibasal crepitations, and there is dullness to percussion of both bases.

Chest X-ray shows small bilateral pleural effusions with upper lobe blood vessel diversion.

What is the most appropriate diagnostic investigation?

- A. Coronary angiography
- B. CT pulmonary angiography
- C. ECG
- D. Echocardiography
- E. Serum D dimer

**32.** An 80 year old man has sudden onset of loss of vision in his right eye. He has hypertension and a previous stroke.

His visual acuity is hand movements only in the right eye and 6/9 in left eye. The right eye has an afferent pupillary defect; left eye pupil responses are normal. On fundoscopy there is a red spot at the right macula.

What is the most likely diagnosis?

- A. Anterior ischaemic optic neuropathy
- B. Branch retinal vein occlusion
- C. Central retinal artery occlusion
- D. Macular degeneration
- E. Retinal detachment



**33.** A 72 year old woman has had inability to sleep well for the past 3 years. She gets to sleep by 23:00 but wakes up two or three times in the night and gets up by 07:00. Her husband says that she doesn't snore. She carries out her normal daytime activities with no daytime somnolence. She is otherwise well.

Her BMI is 23 kg/m<sup>2</sup>. Her MMSE (Mini Mental State Examination) score is 27/30.

What is the most likely cause of her insomnia?

- A. Depression
- B. Early stages of dementia
- C. Hypomania
- D. Normal age related sleep pattern
- E. Obstructive sleep apnoea

**34.** A 35 year old man attends his GP with 3 days of a red, painful left eye with no discharge.

There is a diffuse area of redness in the medial aspect of his left sclera. His pupils and visual acuity are normal.

What is the most appropriate management?

- A. Arrange assessment in emergency eye clinic
- B. Prescribe chloramphenicol eye drops
- C. Prescribe corticosteroid eye drops
- D. Prescribe topical aciclovir
- E. Reassure patient that it will resolve spontaneously



**35.** An 18 year old woman is found dead, sitting in front of a gas fire that is still burning. The flue that carries gases away from the fire is found to be blocked.

What is the principal mechanism of action of the poison involved in her death?

- A. Binding to the site on haemoglobin normally occupied by oxygen
- B. Converting carbon dioxide to carbonic acid in the cytoplasm of peripheral cells
- C. Converting the iron in haem to an iron salt
- D. Damaging the lipid bilayer of alveolar pneumocytes
- E. Inhibiting cytochrome enzyme systems

**36.** A 35 year old man has burning pain in his feet and difficulty sleeping. He has type 1 diabetes mellitus, retinopathy and nephropathy.

Investigation:  
eGFR      28 mL/min/1.73m<sup>2</sup> (> 60)

What is the most appropriate management?

- A. Acupuncture
- B. Amitriptyline
- C. Duloxetine
- D. Physiotherapy
- E. Sodium valproate



**37.** A 24 year old woman has tiredness, bloating and weight loss with bouts of offensive smelling diarrhoea. Abdominal examination is normal.

Investigations:

Haemoglobin	10.0 g/L	(115–150)
Mean cell volume (MCV)	78 fL	(80–96)
Platelets	$350 \times 10^9/L$	(150–400)

Duodenal biopsy shows flattening of villi and increased lymphocytes in the lamina propria and surface epithelium. In addition, there is gross crypt hyperplasia.

What is the most likely diagnosis?

- A. Carcinoid tumour
- B. Coeliac disease
- C. Collagenous enteropathy
- D. Crohn disease
- E. Pseudomembranous enteropathy

**38.** An 87 year old man develops profuse watery diarrhoea 6 days after admission for an infective exacerbation of COPD. He is currently taking oral co-amoxiclav.

What is the most likely causative organism?

- A. Campylobacter jejuni
- B. Clostridioides difficile (Clostridium difficile)
- C. Escherichia coli
- D. Norovirus
- E. Salmonella enteritidis



**39.** A 22 year old woman has worsening shortness of breath and cough productive of four to five tablespoons of sputum per day. She had childhood pneumonia and recurrent chest infections. She coughed up blood on two occasions many years ago.

She has bilateral scattered wheezes and coarse inspiratory crackles.

What is the most likely diagnosis?

- A. Bronchiectasis
- B. COPD
- C. Lung cancer
- D. Pulmonary fibrosis
- E. Sarcoidosis

**40.** A 52 year old woman has had four episodes of severe, colicky epigastric pain associated with vomiting over the past 3 months. The episodes occurred after eating and lasted for about 1 hour before complete resolution. She has type 2 diabetes mellitus and takes metformin.

Abdominal examination is normal. Her BMI is 35 kg/m<sup>2</sup>.

What investigation is most likely to confirm the diagnosis?

- A. Helicobacter stool antigen test
- B. Serum Amylase
- C. Plain abdominal X-ray
- D. Ultrasonography of abdomen
- E. Upper gastrointestinal endoscopy



**41.** An 83 year old woman has recurring dizzy spells. The episodes are associated with transient shaking of her hands that is most noticeable before her lunch and evening meals. She has hypertension and type 2 diabetes mellitus. She takes metformin (1 g twice daily), gliclazide (80 mg twice daily) and ramipril (10 mg daily).

Her BP is 138/82 mmHg lying and 130/78 mmHg standing. Her blood capillary glucose is 6 mmol/L.

Investigations:

Sodium	136 mmol/L	(135-146)
Potassium	5.0 mmol/L	(3.5-5.3)
Urea	3.9 mmol/L	(2.5-7.8)
Creatinine	77 $\mu$ mol/L	(60-120)
Glycated haemoglobin	50 mmol/mol	(20-42)

What is the most appropriate therapeutic change?

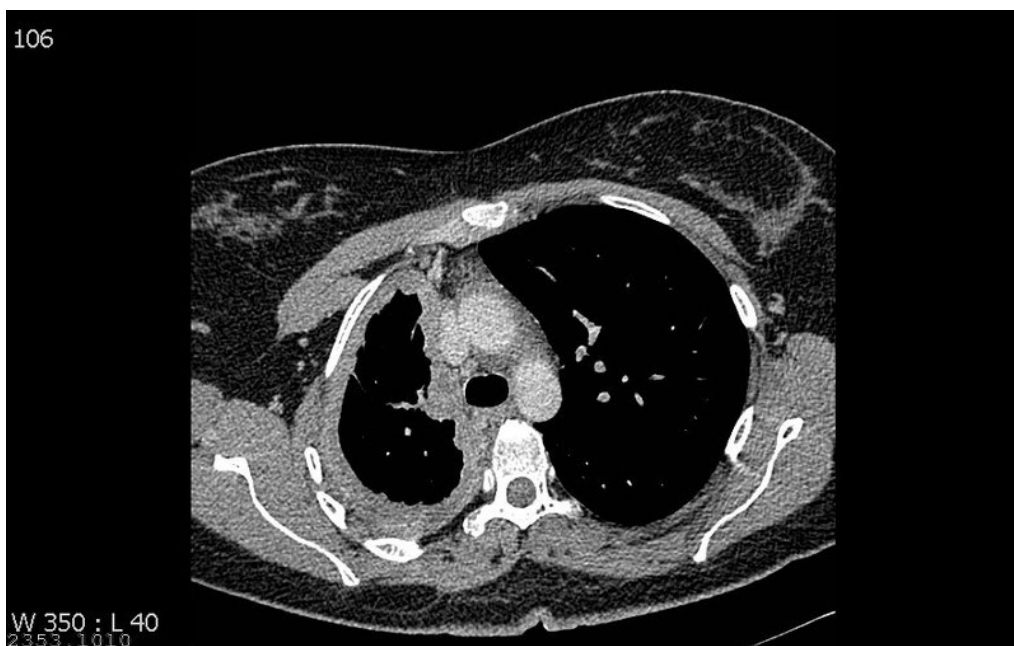- A.** Increase gliclazide dose
- B.** Increase metformin dose
- C.** Reduce gliclazide dose
- D.** Reduce metformin dose
- E.** Reduce ramipril dose

42. A 76 year old woman has progressive breathlessness with right-sided pleuritic chest pain and weight loss over 6 months. She is a retired mechanic and has a 25 pack-year smoking history.

Investigations:

Chest X-ray: marked volume loss in right hemithorax

CT scan of chest: see image



What is the most likely diagnosis?

- A. Asbestosis
- B. Chronic hypersensitivity pneumonitis
- C. Lung cancer
- D. Malignant pleural mesothelioma
- E. Tuberculosis



**43.** A 65 year old woman has severe left-sided abdominal pain. Yesterday, she noticed blood mixed in with her stools. She has no weight loss.

Her temperature is 37.7°C. She is very tender on palpation in the left lower quadrant. No masses are felt on rectal examination, but there is blood on the glove.

What is the most likely cause of her symptoms?

- A. Angiodysplasia
- B. Colorectal cancer
- C. Diverticulitis
- D. Haemorrhoids
- E. Ulcerative colitis

**44.** A 35 year old woman was admitted two days ago after taking 32 paracetamol tablets. She has alcohol use disorder.

Her weight is 40 kg.

She has been treated with a full dose of acetylcysteine.

Which investigation best demonstrates restoration of liver synthetic function?

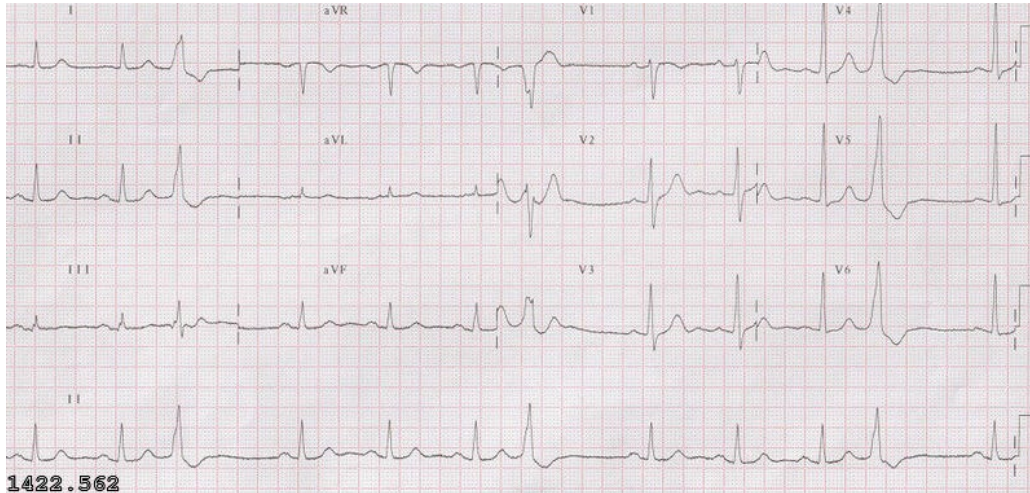
- A. Albumin
- B. ALT
- C. Bilirubin
- D.  $\gamma$ GT
- E. PT



**45.** A 64 year old woman has thumping palpitations and says that she sometimes feels her heart 'gives a sudden jump'. Her husband recently died due to myocardial infarction.

Her pulse is 70 bpm and BP 136/80 mmHg. Her heart sounds are normal.

Her 12-lead ECG is shown in the tracing.



What is the most likely cause of her palpitations?

- A. Atrial fibrillation
- B. Premature supraventricular beats
- C. Premature ventricular beats
- D. Sinus arrhythmia
- E. Ventricular tachycardia

**46.** A 35 year old man has painless swelling of the right side of his scrotum.

The swelling is soft and fluctuant, and transilluminates.

What is the most likely diagnosis?

- A. Hydrocoele
- B. Inguinal hernia
- C. Testicular torsion
- D. Testicular tumour
- E. Varicocele



**47.** A 67 year old woman has an ulcer with a raised white margin on her left ear. The lesion has been present for 3 years, growing slowly and never completely healing. She spent 20 years living in Australia before returning to the UK recently.

She has a small ulcerated area, 4 mm × 6 mm, on her left pinna.

What is the most likely diagnosis?

- A. Actinic keratosis
- B. Basal cell carcinoma
- C. Malignant melanoma
- D. Seborrhoeic keratosis
- E. Squamous cell carcinoma

**48.** A 90 year old man has had 3 days of spasmodic suprapubic pain radiating to the tip of the penis. His long-term urinary catheter has recently been changed. He is mildly confused.

His temperature is 38.2° C, pulse 88 bpm, BP 146/88 mmHg, respiratory rate 15 breaths per minute and oxygen saturation 96% breathing air. Urinalysis: dark and strong smelling, protein 1+, blood 1+, negative for leucocytes and nitrites.

Which factor(s) indicate(s) the need to start antibiotics?

- A. Blood and protein in urine
- B. Dark strong-smelling urine
- C. Fever and mild confusion
- D. Presence of pain
- E. Recent catheter change



**49.** A 68 year old woman attends her GP with intermittent palpitations. She has diet-controlled type 2 diabetes.

Her pulse is 78 bpm, regular. BP 121/77 mmHg.

Investigations:

Haemoglobin	137 g/L	(115–150)
eGFR	85 mL/min/1.73m <sup>2</sup>	(> 60)

24 hour ECG: Normal sinus rhythm with a single episode of irregularly irregular rhythm with absent P waves, and normal QRS complexes lasting 15 minutes. Ventricular rate 110 beats per minute during the episode.

What is the most appropriate initial management?

- A. Start apixaban 5 mg twice daily
- B. Start aspirin 75mg once daily
- C. Start digoxin 125 micrograms once daily
- D. Give digoxin 75 micrograms stat
- E. Refer for left atrial ablation

**50.** A 48 year old man has visible haematuria and right loin pain.

His temperature is 37.3°C, pulse 72 bpm and BP 170/97 mmHg. Masses are palpable in both flanks.

Investigations:

Creatinine	220 µmol/L	(60-120)
Urinalysis:	blood 4+	

What is the most appropriate next investigation?

- A. CT scan of kidneys, ureters and bladder
- B. Cystoscopy
- C. MR scan of renal tract
- D. Ultrasound scan of renal tract
- E. Urine cytology



**51.** A 35 year old man attends his GP with a severe frontal headache of 12 hours' duration. It started suddenly, reaching maximum intensity within 1 minute. He has associated nausea. At the onset of his headache he noticed a small hole in his vision. This hole started centrally, moved to the edge of his vision and has now resolved. The headache is worse in bright light.

Paracetamol has not helped his pain.

Which feature should prompt immediate referral to hospital?

- A. Abrupt onset
- B. Failure to respond to paracetamol
- C. Nausea
- D. Photophobia
- E. Visual disturbance

**52.** A 28 year old man has an insurance medical.

His pulse is 72 bpm and BP 210/110 mmHg. There is radiofemoral delay. A systolic murmur is audible on auscultation.

Chest X-ray reveals notching of the ribs in the mid-clavicular line.

What is the most likely diagnosis?

- A. Coarctation of the aorta
- B. Dissecting aortic aneurysm
- C. Marfan syndrome
- D. Renal artery stenosis
- E. Takayasu arteritis

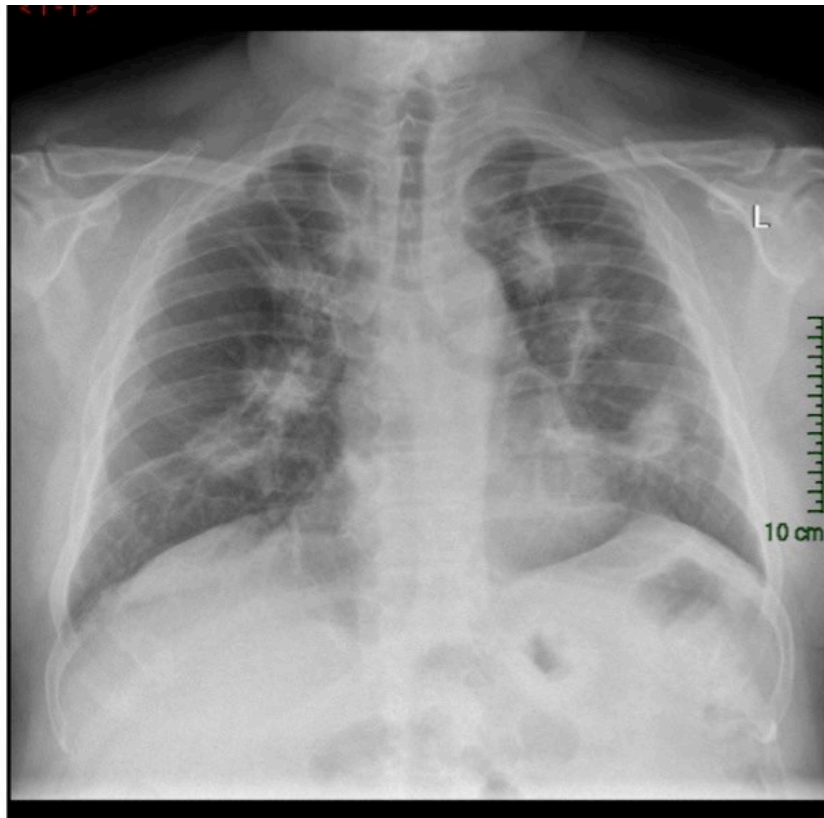


**53.** A 42 year old woman has two episodes of haemoptysis. She also reports two months of sinusitis with pain, stuffiness and nose bleeds. She has some loosening of her teeth and painful oral ulceration. Previously, she noticed a rash and nodules over her elbows but they have disappeared.

Investigations:

Chest X-ray: see image

Urinalysis: occasional red cell casts



What is the most likely diagnosis?

- A. Behçet disease
- B. Granulomatosis with polyangiitis
- C. Metastatic nasopharyngeal carcinoma
- D. Syphilis
- E. Tuberculosis



**54.** A 19 year old man has had a sore throat, malaise and intermittent fever for 2 weeks.

His pulse is 74 bpm and BP 115/75 mmHg. His throat is red and tonsils are swollen. His sclerae are yellow-tinged. There are multiple soft palpable lymph nodes in the neck. There is tenderness in the right upper abdominal quadrant.

What is the most appropriate diagnostic investigation?

- A. Epstein–Barr virus test
- B. HIV test
- C. Lymph node biopsy for histology
- D. Mantoux test
- E. Throat swab and culture

**55.** A 27 year old woman has had abdominal pain for 48 hours. She also reports recurrent mouth ulcers and altered bowel habit for a few weeks.

Her temperature is 37.5°C. She has central abdominal tenderness.

Investigations:

CT colonoscopy shows a normal appendix with distal small bowel thickening. There are enlarged nodes in the small bowel mesentery.

What is the most likely diagnosis?

- A. Crohn ileitis
- B. Intestinal tuberculosis
- C. Meckel diverticulitis
- D. Mesenteric adenitis
- E. Small bowel lymphoma



**56.** A 34 year old man has cough and weight loss.

A diagnosis of tuberculosis is confirmed and treatment is started. As part of his monitoring, he is screened for loss of visual acuity.

Which antituberculosis drug is an indication for visual monitoring?

- A. Ethambutol hydrochloride
- B. Isoniazid
- C. Moxifloxacin
- D. Pyrazinamide
- E. Rifampicin

**57.** A 21 year old woman attends her GP with moderately severe acne. She has tried topical retinoids and topical antibiotics without satisfactory response. She previously had a deep vein thrombosis following a long-haul flight.

What is the most appropriate treatment?

- A. Co-cyprindiol
- B. Desogestrel
- C. Flucloxacillin
- D. Isotretinoin
- E. Lymecline



**58.** A 45 year old man has had weight loss, fatigue and polyuria for 3 months. He takes a number of multivitamin preparations.

Clinical examination is unremarkable.

Investigations:

Serum corrected calcium	2.9 mmol/L	(2.2–2.6)
Phosphate	0.82 mmol/L	(0.8–1.5)
Serum alkaline phosphatase	154 IU/L	(25–115)
Parathyroid hormone	7.9 pmol/L	(1.6–8.5)

Serum electrolytes and urea are normal.

What is the most likely diagnosis?

- A. Bony metastases
- B. Excess calcium intake
- C. Primary hyperparathyroidism
- D. Sarcoidosis
- E. Vitamin D excess

**59.** A 59 year old man has a 1 year of erectile dysfunction. He has angina, type 2 diabetes mellitus and peripheral vascular disease. He had a thyroidectomy 2 years ago for thyrotoxicosis. He takes aspirin, diltiazem, levothyroxine, metformin, ramipril and simvastatin.

His BP is 140/90 mmHg lying and 135/85 mmHg standing. His foot pulses are not palpable. He has normal sensation in his feet.

What is most likely to be the main cause of his erectile dysfunction?

- A. Adverse effect of medication
- B. Autonomic neuropathy
- C. Hypothyroidism
- D. Testosterone deficiency
- E. Vascular insufficiency



**60.** A 52 year old man has had 3 months of fatigue. He has ulcerative colitis and takes mesalazine. He drinks 20 units of alcohol per week.

His temperature is 36.8°C and pulse 80 bpm. He has 3 cm hepatomegaly.

Investigations:

Albumin	36 g/L	(35–50)
ALT	65 IU/L	(10–50)
ALP	580 IU/L	(25–115)
Bilirubin	18 µmol/L	(<17)
γGT	230 IU/L	(9–40)

What is the most likely diagnosis?

- A. Alcoholic hepatitis
- B. Cholangiocarcinoma
- C. Choledocholithiasis
- D. Hepatocellular carcinoma
- E. Primary sclerosing cholangitis

**61.** A 73 year old man has increasing breathlessness over 1 week. He has chronic kidney disease and ischaemic heart disease. He takes alfacalcidol, aspirin, atorvastatin, bisoprolol fumarate, furosemide and irbesartan.

There are bibasal inspiratory crepitations and mild peripheral oedema.

Investigations:

Sodium	134 mmol/L	(135–146)
Potassium	6.7 mmol/L	(3.5–5.3)
Urea	19 mmol/L	(2.5–7.8)
Creatinine	259 µmol/L	(60–120)
eGFR	23 mL/min/1.73 m <sup>2</sup>	(>60)

Which drug is most likely to be contributing to his hyperkalaemia?

- A. Alfacalcidol
- B. Aspirin
- C. Bisoprolol fumarate
- D. Furosemide
- E. Irbesartan



**62.** A 65 year old man is invited to the abdominal aortic aneurysm screening programme.

An ultrasound scan shows his abdominal aorta to be 33 mm in diameter.

What is the most appropriate management plan?

- A. Reassure and discharge
- B. Refer for angiography
- C. Refer for vascular surgery
- D. Repeat ultrasound scan in 12 months
- E. Request CT scan of abdomen

**63.** A 28 year old woman has pain on swallowing. She has asthma that is well controlled using metered dose salbutamol and beclometasone dipropionate (800 micrograms/day) inhalers.

She has white plaques in her mouth.

An anti-fungal oral suspension is prescribed.

What is the most appropriate management with regard to her beclometasone?

- A. Change beclometasone dipropionate to a dry powder formulation
- B. Change beclometasone dipropionate to fluticasone
- C. Change beclometasone dipropionate to salmeterol
- D. Take beclometasone dipropionate using a large volume spacer
- E. Take salbutamol and beclometasone dipropionate at least 1h apart



**64.** A 37 year old man has increasing fever and shortness of breath. He was admitted 3 days ago with left lower lobe pneumonia due penicillin-sensitive *Streptococcus pneumoniae*. He is receiving intravenous benzylpenicillin 1.2 g four times daily.

His temperature is 38.5°C, pulse 100 bpm and BP 122/80 mmHg.

Investigations:

Chest X-ray: left basal effusion.

Diagnostic pleural aspiration: Purulent fluid. Microscopy shows numerous polymorphs and Gram-positive cocci

What is the most appropriate next step in management?

- A. Chest drain insertion
- B. Increase dose of benzylpenicillin
- C. Open thoracostomy
- D. Switch benzylpenicillin to ceftriaxone
- E. Switch benzylpenicillin to vancomycin

**65.** A 52 year old man has 4 weeks of joint pain, fever and weight loss. He is a non-smoker and has no significant medical history.

Examination is unremarkable.

Investigations:

Calcium	3.12 mmol/L	(2.2–2.6)
Plasma parathyroid hormone	<0.5 pmol/L	(0.9–5.4)

Chest X-ray shows perihilar lymphadenopathy.

What is the most likely diagnosis?

- A. Granulomatosis with polyangiitis
- B. Hodgkin lymphoma
- C. Primary hyperparathyroidism
- D. Sarcoidosis
- E. Tuberculosis



**66.** The daughter of a 78 year old man is concerned about an area of redness on her father's back. He lives alone and spends most of his day sitting in a chair.

There is a reddened area over the sacrum, but his skin is intact.

He is considered to be at risk of pressure ulcers.

Which member of the community multidisciplinary team would be most suited to conduct an initial assessment?

- A. Dietician
- B. District nurse
- C. Occupational therapist
- D. Physiotherapist
- E. Tissue viability nurse

**67.** A doctor in training sustains a needle-stick injury while inserting a venous cannula into a patient. The patient has a history of intravenous drug use.

What is the most important first action for the doctor in training?

- A. Encourage bleeding from the needle-stick injury wound
- B. Make an appointment with occupational health
- C. Seek post-exposure prophylaxis
- D. Test the patient for HIV
- E. Get an immediate blood sample taken from themselves



**68.** A 32 year old woman has 3 weeks of fever, rigors and lethargy. In the past week, she has also become breathless on exertion. She is an intravenous drug user.

Her temperature is 38°C, pulse 100 bpm regular, and BP 100/60 mmHg. Her JVP is raised with predominant V waves. There is a pansystolic murmur at the left sternal edge on inspiration. She has reduced air entry with dullness to percussion at the right lung base. She has swelling of both ankles.

What is the most likely pathogen?

- A. Enterococcus faecalis
- B. Staphylococcus aureus
- C. Staphylococcus epidermidis
- D. Streptococcus bovis / streptococcus equinus complex
- E. Streptococcus viridans

**69.** A 34 year old woman has sudden onset of right arm weakness and inability to speak. She has migraines and generalised joint pains. Four years ago, she had a deep vein thrombosis in her right leg.

Her pulse is 68 bpm and BP 178/94 mmHg. She has an expressive dysphasia. She has flaccid weakness of her right arm and facial droop on the right lower half of her face.

Investigations:

Haemoglobin	118 g/L	(115–150)
White cell count	$4.3 \times 10^9/L$	(3.8–10.0)
Neutrophils	$2.1 \times 10^9/L$	(2.0–7.5)
Lymphocytes	$0.6 \times 10^9/L$	(1.1–3.3)
Platelets	$132 \times 10^9/L$	(150–400)
Total cholesterol	4.6 mmol/L	(<5.0)

CT scan of head left frontoparietal infarct

What additional investigation is most likely to reveal the underlying cause of her stroke?

- A. Anti-dsDNA antibody
- B. Anticardiolipin antibody
- C. Anti-Ro antibody
- D. Rheumatoid factor
- E. Serum immunoglobulins



**70.** A 55 year old woman has been feeling tired and sleepy. Her partner says that she snores heavily. She has type 2 diabetes mellitus and takes metformin.

Her BMI is 38 kg/m<sup>2</sup>. Her oxygen saturation is 95% breathing air. Her Epworth sleepiness score is 19 (normal <11). Her HbA1C is 60 mmol/mol (20-42).

What treatment is most likely to improve her daytime somnolence?

- A. Bariatric surgery
- B. Continuous positive airway pressure ventilation
- C. Long acting insulin
- D. Mandibular advancement device
- E. Modafinil

**71.** A 72 year old man has had six months of increased frequency of defaecation and three months of dark red rectal bleeding mixed with the stool.

Investigations:

Haemoglobin	101 g/L	(130–175)
Mean cell haemoglobin (MCH)	24 pg	(27–33)
MCV	73 fL	(80–96)
White cell count	9.1 x 10 <sup>9</sup> /L	(3.0–10.0)
Platelets	354 x 10 <sup>9</sup> /L	(150–400)

What is the most likely diagnosis?

- A. Colonic carcinoma
- B. Diverticular disease
- C. Haemorrhoids
- D. Ischaemic colitis
- E. Ulcerative colitis



**72.** A 24 year old man is reviewed following a recent orchidectomy.

The pathologist's report describes a mass with cystic spaces. Histological examination shows areas of mature cartilage and columnar epithelium.

What is the most likely diagnosis?

- A.** Chondrosarcoma
- B.** Hamartoma
- C.** Lymphoma
- D.** Seminoma
- E.** Teratoma

**73.** A 50 year old man has had increasing breathlessness when climbing the stairs. He has no chest pain, wheeze or cough. He has COPD. He takes a salbutamol inhaler several times per day. He used to smoke until 3 months ago and has a 30 pack-year smoking history. His weight is stable and he is otherwise well.

Investigation:  
FEV1 : 75% predicted

What is the most appropriate next step in pharmacological management?

- A.** Inhaled beclometasone
- B.** Inhaled tiotropium and salmeterol
- C.** Nebulised salbutamol and ipratropium bromide
- D.** Oral prednisolone
- E.** Oral theophylline



**74.** An 86 year old woman has had three falls in the past 3 months. On each occasion, she describes feeling lightheaded and dizzy prior to falling. She is taking alendronic acid, amlodipine, atorvastatin, metformin and zolpidem tartrate.

Her BP is 132/80 mmHg sitting and 138/84 mmHg standing.

Which medication is most likely to be contributing to her falls?

- A. Alendronic acid
- B. Amlodipine
- C. Atorvastatin
- D. Metformin
- E. Zolpidem tartrate

**75.** A 45 year old man has had 6 months of tiredness, reduced libido and erectile dysfunction.

Investigations:

Testosterone	1.8 nmol/L	(9.9–27.8)
LH	1.2 U/L	(1–8)
FSH	1.0 U/L	(1–12)

What is the most likely cause of his presentation?

- A. Anabolic steroid misuse
- B. Androgen insensitivity syndrome
- C. Congenital adrenal hyperplasia
- D. Klinefelter syndrome
- E. Pituitary adenoma



**76.** A 40 year old man develops sudden breathlessness 5 days after an acute inferior ST-elevation myocardial infarction treated by primary coronary intervention.

His pulse is 110 bpm, BP 110/75 mmHg, respiratory rate 22 breaths per minute and oxygen saturation 92% breathing 28% oxygen via Venturi mask. There is a pansystolic murmur at the apex and bibasal inspiratory crackles.

What is the most likely cause of this presentation?

- A.** Acute pulmonary embolus
- B.** Aortic regurgitation
- C.** Cardiac tamponade
- D.** Papillary muscle rupture
- E.** Pericarditis

**77.** A 48 year old man attends the GP surgery with headaches. He has noticed that his hands have become larger, and his facial features have coarsened. More recently, his vision has deteriorated.

He has an upper temporal defect in both visual fields.

Damage to which structure is the most likely source of his visual problems?

- A.** Lateral geniculate body
- B.** Occipital cortex
- C.** Oculomotor nerve
- D.** Optic chiasm
- E.** Optic radiation



**78.** A 42 year old man has a rash on his face, mainly around his chin. The rash started 24 hours ago with a 0.5 cm thin-walled blister that then ruptured, leaving a yellow crusted lesion that has since enlarged and now other similar lesions are appearing in the same area. He is a primary school teacher.

What is the most likely causative organism?

- A. Escherichia coli
- B. Pseudomonas aeruginosa
- C. Staphylococcus aureus
- D. Streptococcus pyogenes
- E. Varicella zoster virus

**79.** A 48 year old woman has had 3 years of increasing knee pain and reduced physical activity. She has radiologically-confirmed osteoarthritis. She has hypertension and type 2 diabetes. She takes lisinopril, metformin, semaglutide and simvastatin. Her BMI is 48 kg/m<sup>2</sup> and has not changed despite lifestyle advice and a low calorie diet for the last year.

Investigations:

Glycated haemoglobin      55 mmol/mol      (20-42)

What is the most appropriate management?

- A. Intensify lifestyle measures and review in 6 months
- B. Prescribe orlistat
- C. Refer for bariatric surgery
- D. Refer for bilateral knee replacements
- E. Start insulin therapy



**80.** A 22 year old soldier steps off a cramped military aircraft following a long flight from the UK. She suddenly collapses and hits her head on the ground. While unconscious, she has asynchronous jerking of her limbs for less than 15 seconds. Witnesses say that she looked pale. She regains consciousness within 1 minute.

What is the most likely cause of her collapse?

- A. Cardiac arrhythmia
- B. Epilepsy
- C. Hypoglycaemia
- D. Pulmonary embolism
- E. Vasovagal syncope

**81.** A 62 year old man has 2 months of increasing shortness of breath and chest pain. He is now unable to lie flat. For the past 2 weeks, he has also had a productive cough which was flecked with blood on two occasions. He had a myocardial infarction 6 months ago, at which point he stopped smoking.

His temperature is 37.1°C, BP 126/66 mmHg, respiratory rate 24 breaths per minute and oxygen saturation 93% breathing air.

Investigations:

Chest X-ray: moderate right-sided pleural effusion.

Pleural aspirate protein content 56 g/L.

What is the most likely underlying diagnosis?

- A. Bacterial pneumonia
- B. Heart failure
- C. Lung cancer
- D. Pulmonary embolism
- E. Tuberculosis



**82.** A 55 year old man is referred to the vascular outpatient clinic with bilateral claudication, limiting his walking distance to 10 metres. He smokes.

Imaging shows chronic distal aortic and bilateral common iliac occlusive disease.

What is the most appropriate surgical intervention?

- A. Aortic endarterectomy
- B. Aorto-bifemoral bypass graft
- C. Aorto-iliac embolectomy
- D. Bilateral iliac angioplasty
- E. Femoral-to-femoral crossover graft

**83.** A 65 year old man attends his GP for monitoring of hypertension and ischaemic heart disease. He takes aspirin, atenolol, amlodipine, lisinopril and simvastatin.

He has marked ankle swelling.

Which drug is the most likely cause of his ankle swelling?

- A. Amlodipine
- B. Aspirin
- C. Atenolol
- D. Lisinopril
- E. Simvastatin



**84.** An 85 year old woman was admitted with a stroke three weeks ago. She has urinary incontinence and a long-term urinary catheter in situ. She takes clopidogrel and ramipril.

Her temperature is 36.8°C, pulse 85 bpm and BP 134/74 mmHg.

A catheter specimen of urine shows  $>10^5$ CFU/mL, mixed growth.

What is the most appropriate management?

- A. No change in treatment
- B. Remove urinary catheter
- C. Request antibiotic sensitivities
- D. Start oral ciprofloxacin
- E. Start oral trimethoprim

**85.** A 28 year old man has a headache, intermittent fever, sore throat and diarrhoea.

His temperature is 37.7°C. His fauces are red and there are two small aphthous ulcers on his left buccal mucosa. He also has a maculopapular erythematous rash on his upper trunk, red hands and folliculitis on his chest. His liver and spleen are just palpable and he has mild neck stiffness.

Investigations:

Haemoglobin	135 g/L	(130–175)
White cell count	$3.3 \times 10^9$ /L	(3.0–10.0)
Platelets	$84 \times 10^9$ /L	(150–400)

What investigation is most likely to lead to a diagnosis?

- A. First catch urine microscopy
- B. Glandular fever screening test
- C. HIV serology
- D. Serum antinuclear antibodies
- E. Serum toxoplasma gondii IgM antibody titre



**86.** A 78 year old woman is found dead at home. At autopsy, the pathologist finds bilateral pneumonia and meningitis.

Microscopy of a meningeal swab shows Gram-positive cocci arranged in pairs.

What is the most likely causative organism?

- A. *Candida albicans*
- B. *Neisseria meningitidis*
- C. *Pseudomonas aeruginosa*
- D. *Staphylococcus aureus*
- E. *Streptococcus pneumoniae*

**87.** A 55 year old man attends the GP surgery concerned that he may be a carrier of cystic fibrosis. The condition has just been diagnosed in his 5 year old grandson. He has heard that this is an inherited condition, but no one else in his family has the illness.

What is the likelihood that the grandfather is a carrier?

- A. 1 in 2
- B. 1 in 4
- C. 1 in 8
- D. 1 in 16
- E. 1 in 25



**88.** A 79 year old woman has been repeatedly found wandering at night by her neighbours. This has progressively worsened over 6 months. She is independent in her activities of daily living, although her family do her shopping. She was previously well.

Based on the likely diagnosis, what aspect of cognition is likely to show the greatest impairment?

- A. Attention
- B. Concentration
- C. Praxis
- D. Registration of information
- E. Short-term memory

**89.** A 52 year old woman has increased urinary frequency, urgency and urge incontinence. She has multiple sclerosis, which affects her walking.

A midstream urine sample shows no cells and is sterile on culture. A bladder scan shows a residual volume of 300 mL. Urodynamic assessment shows that she has a neuropathic bladder.

What is the most appropriate management?

- A.  $\alpha$ -Adrenoceptor blocker
- B. Anticholinergic drug
- C. Indwelling urethral catheter
- D. Intermittent self catheterisation
- E. Suprapubic catheter



**90.** An 84 year old man develops profuse diarrhoea whilst in hospital. An outbreak of *Clostridioides (Clostridium) difficile* has occurred in his ward.

Which feature of this organism makes it particularly difficult to destroy?

- A. Motility
- B. Outer capsule
- C. Rapid mutation
- D. Spore formation
- E. Surface adherence

**91.** A 40 year old man was admitted with central crushing chest pain.

He has pale cream coloured nodules on both elbows and medial aspects of his upper eyelids.

ECG on admission showed ST elevation and T wave inversion.

He deteriorated and died. A post mortem examination is performed and shows very severe narrowing of the anterior descending branch of the left coronary artery.

What is the most likely causative mechanism?

- A. Atheroma
- B. Arterial dissection
- C. Malignant deposit
- D. Thrombosis
- E. Vasculitis



**92.** A 60 year old man has 6 months of dry cough and increasing shortness of breath on effort. He was previously fit and well, and does not smoke.

His temperature is 36.8°C, pulse 60 bpm and oxygen saturation 89% breathing air.

He has finger clubbing. Cardiac examination is normal, and chest examination reveals bibasal crepitations.

What is the most likely diagnosis?

- A.** Bronchiectasis
- B.** Extrinsic allergic alveolitis
- C.** Idiopathic pulmonary fibrosis
- D.** Lung carcinoma
- E.** Pulmonary tuberculosis

**93.** A 65 year old man attends the anticoagulant clinic. He has had a metal mitral valve replacement and atrial fibrillation. He takes warfarin 7 mg daily.

His pulse is 70 bpm, irregularly irregular, with a mechanical second heart sound. There are no signs of bleeding.

His INR is 5.1.

What is the most appropriate next step in management?

- A.** Continue warfarin at lower dose
- B.** Continue warfarin at same dose
- C.** Give vitamin K intravenously
- D.** Give vitamin K orally
- E.** Withhold warfarin for 2 days then restart at lower dose



**94.** A 55 year old man is rescued from a collapsed building where he has been trapped for 12 hours without water.

His temperature is 35.6°C, pulse 100 bpm and BP 90/42 mmHg. His JVP is not visible. His abdomen is non tender.

Investigations:

Haemoglobin	168 g/L	(130–175)
Sodium	148 mmol/L	(135–146)
Potassium	6.0 mmol/L	(3.5–5.3)
Urea	25.1 mmol/L	(2.5–7.8)
Creatinine	184 µmol/L	(60–120)
Creatine kinase	840 U/L	(25–200)

What is the most likely cause of this biochemical picture?

- A. Bladder outflow obstruction
- B. Direct renal trauma
- C. Hypovolaemia
- D. Rhabdomyolysis
- E. Sepsis

**95.** A 56 year old man has had a single episode of painless visible haematuria. He has no other urinary symptoms and is otherwise fit and well. He has smoked ten cigarettes per day for the past 35 years.

His BP is 140/85 mmHg. Urinalysis performed after this episode shows blood 2+, no protein and no nitrites.

Investigations:

Urea	6.5 mmol/L	(2.5–7.8)
Creatinine	95 µmol/L	(60–120)

Urine culture: no growth

What investigation is most likely to confirm the diagnosis?

- A. Flexible cystoscopy
- B. Serum prostate specific antigen
- C. Transrectal ultrasound scan of prostate
- D. Ultrasound scan of kidneys
- E. Urine cytology



**96.** A 81 year old man has three months of malaise, bleeding gums and pain in his legs. He has been struggling to look after himself since his wife died one year ago. He has a poor diet and reports that he mostly has tea and toast.

He has gingival hypertrophy and skin petechiae.

What micronutrient deficiency is most likely to account for his symptoms?

- A. Magnesium
- B. Vitamin A
- C. Vitamin B1
- D. Vitamin C
- E. Zinc

**97.** A 24 year old man is admitted to hospital with an exacerbation of asthma.

His symptoms improve with treatment, and he is ready for discharge after 24 hours. His discharge medication includes a combined beclometasone and salmeterol inhaler, and a short course of oral prednisolone.

What further management must be provided prior to discharge?

- A. Antibiotic rescue pack
- B. Course of antihistamines
- C. Nebuliser machine for use at home
- D. Personalised asthma action plan
- E. Volumatic spacer device



**98.** A 79 year old woman has 6 months of increasing breathlessness on exertion.

Her pulse is 72 bpm, irregularly irregular, and BP 118/72 mmHg. She has a low-pitched, mid-diastolic murmur best heard at the apex in expiration.

What is the most likely cause of her murmur?

- A. Aortic regurgitation
- B. Aortic stenosis
- C. Hypertrophic cardiomyopathy
- D. Mitral regurgitation
- E. Mitral stenosis

**99.** A 43 year old woman is admitted with acute right upper quadrant pain, which radiates to her right shoulder.

Her temperature is 38.6°C and respiratory rate 20 breaths per minute. She is tender to palpation in the right upper quadrant but has no rebound tenderness.

Investigations:

Haemoglobin	132 g/L	(115–150)
White cell count	$13 \times 10^9/L$	(3.8–10.0)
Platelets	$340 \times 10^9/L$	(150–400)
Bilirubin	30 $\mu\text{mol/L}$	(<17)
Alanine aminotransferase (ALT)	80 IU/L	(10–50)
Alkaline phosphatase	306 IU/L	(25–115)

What is the next most appropriate radiological test?

- A. Abdominal X-ray
- B. CT scan of abdomen
- C. Erect chest X-ray
- D. MR scan of abdomen
- E. Ultrasound scan of abdomen



**100.** A 41 year old man is admitted with an acute myocardial infarction. His father died of a myocardial infarction aged 52 years.

Investigations:

Fasting glucose            8.2 mmol/L    (3.0–6.0)

Cholesterol (fasting)    9.2 mmol/L    (3.5–6.5)

Triglycerides (fasting)  1.9 mmol/L    (<2.3)

HDL cholesterol           1.0 mmol/L    (>1.2)

What is the most likely cause of his hyperlipidaemia?

- A.** Chylomicronaemia
- B.** Diabetes mellitus
- C.** Familial combined hyperlipidaemia
- D.** Heterozygous familial hypercholesterolaemia
- E.** Polygenic hypercholesterolaemia