

UK Medical School AKT Practice Exam

The MS AKT Exam Board has put together a 200-item practice exam (2 x 100 item papers) to help medical students prepare for the UK Medical School Applied Knowledge Test (MS AKT). Blueprinted to the GMC Content Map this exam has been designed to reflect the style and type of question that students will encounter when the MS AKT goes live in 2024-25 or 2023-24 for schools that have penultimate year exams.

The practice exam comes with and without the answer options.

We would like to recognise the contribution of medical schools, and members of the AKT Exam Board in particular, in producing this exam which we hope students will find a valuable resource.

Should you have any questions about the clinical content of the practice exam please speak to the Assessment Lead in your school in the first instance.

Any redistribution or reproduction of part or all of the contents in any form is prohibited other than for personal, educational and non-commercial use.

MS AKT Practice Exam with answers

Paper 2

1. A 25 year old man has had penile pain for two days. His most recent sexual intercourse was one week ago.

There are multiple tender ulcers on his preputial skin. His penile and scrotal skin does not have any other abnormality.

Which is the most likely diagnosis?

- A. Genital warts
- B. Gonorrhoea
- C. Herpes simplex
- D. Lymphogranuloma venereum
- E. Syphilis

Correct Answer: C

2. A 60 year old man has increasing left hip pain. It is worse after exercise and occasionally wakes him at night. He has stiffness in the mornings that lasts for about 10 minutes. He has hypertension treated with ramipril, but is otherwise in good health.

He has reduced internal rotation on passive movement. This also elicits pain.

Which is the most appropriate initial treatment for his pain?

- A. Celecoxib
- B. Codeine phosphate
- C. Naproxen
- D. Paracetamol
- E. Tramadol

Correct Answer: D

3. An 18 year old woman is 19 weeks pregnant. An ultrasound scan shows her baby has anencephaly. She wants to discuss her options with regards to termination of pregnancy.

When will termination of this pregnancy be legally permitted?

- A. After spontaneous fetal death
- B. At any time during the pregnancy
- C. Before 20 weeks' gestation
- D. Before 24 weeks' gestation
- E. Before 28 weeks' gestation

Correct Answer: B

4. A 65 year old man has had constant back and right knee pain for 6 months, partially relieved by analgesia. He is an ex-smoker. He is otherwise well.

Investigations:

Haemoglobin 132 g/L (130-175)

Alkaline phosphatase 850 IU/L (25-115)

Calcium 2.3 mmol/L (2.2-2.6)

Phosphate 0.9 mmol/L (0.8-1.5)

Prostate specific antigen 5 µg/L (<4.0)

X-rays: sclerotic areas in lower right femur and lumbar spine L3

Isotope bone scan: areas of increased uptake in femur, lumbar spine and skull

Which is the most likely diagnosis?

- A. Hyperparathyroidism
- B. Metastatic carcinoma of prostate
- C. Metastatic small cell carcinoma of lung
- D. Myeloma
- E. Paget's disease of bone

Correct Answer: E

5. A 14 year old girl has had crampy abdominal pain and poor appetite for 24 hours. She has also had a sore throat for 3 days.

Her temperature is 38.5°C. There is cervical lymphadenopathy and tenderness in the right iliac fossa.

Which is the most likely diagnosis?

- A. Acute appendicitis
- B. Crohn's ileitis
- C. Meckel's diverticulum
- D. Mesenteric adenitis
- E. Ovarian cyst

Correct Answer: D

6. The links between deprivation and health inequalities are well evidenced and widely accepted, but there are a number of explanations for that association. One explanation proposes that ill health determines people's social class.

Which type of explanation of health inequality is this?

- A. Artefact
- B. Cultural/behavioural
- C. Idealist
- D. Materialist
- E. Social selection/mobility

Correct Answer: E

7. A 19 year old man has 1 day of fever, muscle stiffness, palpitations and difficulty breathing. He has a history of psychotic depression. He has been taking fluoxetine for 6 weeks and started taking risperidone 1 week ago.

He is agitated and distressed. His temperature is 39.8°C, pulse rate 114 bpm, BP 172/89 mmHg and respiratory rate 30 breaths per minute. Chest examination is otherwise normal. There is increased tone globally; there are no other neurological abnormalities.

Which test is most likely to help confirm the diagnosis?

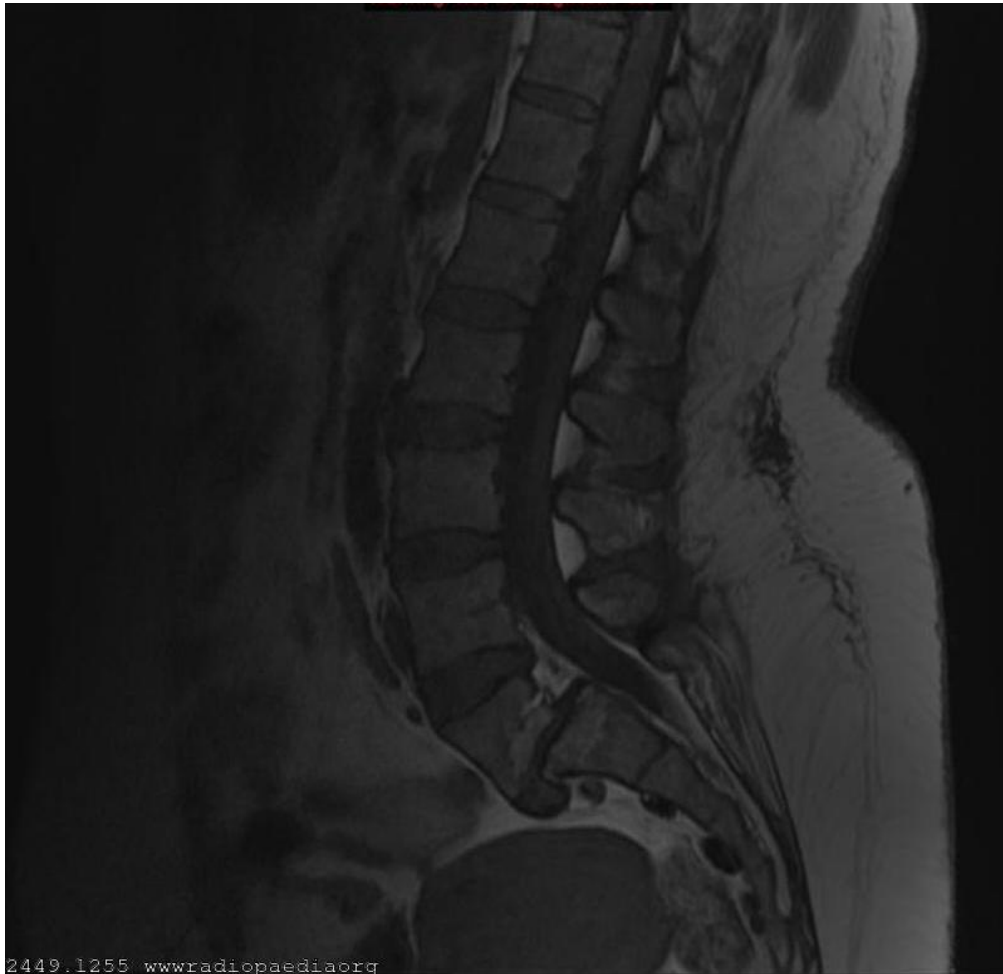- A. CT scan of head
- B. ECG
- C. EEG
- D. Lumbar puncture
- E. Serum creatine kinase

Correct Answer: E

8. A 43 year old man is involved in a low speed road traffic collision. Following this he develops pain in his lower back that it is still troublesome several months later. The pain is worse after activity and is relieved by rest.

He has an exaggerated lumbar lordosis with a palpable depression above L5. The range of movement of his spine is grossly normal. Neurological examination of his lower limbs is also normal.

An MR scan is obtained (see image).



9. 2449.1255 wwwradiopaedia.org

What is the diagnosis?

- A. Cauda equina syndrome
- B. Compression fracture
- C. Herniated intervertebral disc
- D. Spondylolisthesis
- E. Spondylosis

Correct Answer: D

10. A 30 year old man goes out gambling. One night he makes a profit of £100,000, and the following night he loses £150,000.

Which psychological process most likely occurred on the first night that led to his risk taking on the following night?

- A. Classical conditioning
- B. Disinhibition
- C. Modelling
- D. Positive reinforcement
- E. Social learning

Correct Answer: D

10. A 85 year old woman has a breast lump. She has hypertension, heart failure and a previous stroke. Her medications are bisoprolol, ramipril, furosemide, aspirin and atorvastatin.

Her pulse is 76 bpm irregularly irregular and BP 105/70 mmHg. Her jugular venous pressure is visible 6 cm above the sternal angle. She has bibasal late inspiratory crepitations and bilateral pedal oedema. There is a 2.5 cm diameter, mobile, hard, non tender swelling in the upper outer quadrant of her breast. There is no palpable lymphadenopathy.

Investigation:

Pathology report of breast biopsy: infiltrating ductal carcinoma, ER positive, HER2 negative

She is started on an aromatase inhibitor and bisphosphonate.

Which is the most appropriate next treatment to offer?

- A. Chemotherapy
- B. Immunotherapy
- C. No additional treatment
- D. Radiotherapy
- E. Surgery

Correct Answer: C

11. A 40 year old primigravid woman, at 28 weeks' gestation, is admitted with a seizure. She had epigastric pain and blurred vision preceding the seizure.

Her BP is 155/105 mmHg. Reflexes are brisk with two beats of ankle clonus.
Her urinalysis shows protein 2+.

Which intravenous drug is the most appropriate immediate treatment?

- A. Diazepam
- B. Hydralazine
- C. Levetiracetam
- D. Magnesium sulfate
- E. Phenytoin

Correct Answer: D

12. A 29 year old woman visits her GP with a heavy sensation in her vagina when exercising. She is aware of a bulge in her vagina, sometimes associated with a desire to void urine. She had a vaginal delivery 2 years ago.

There is some laxity of the anterior vaginal wall, but this does not descend to the introitus on straining. Urine culture is negative.

Which is the most appropriate management plan?

- A. Oxybutinin hydrochloride
- B. Pelvic floor exercises
- C. Refer for urodynamic testing
- D. Refer to urogynaecology clinic
- E. Ultrasound scan of pelvis

Correct Answer: B

13. A 19 month old girl has been able to sit unsupported for 1 month. She can speak 11 words and feeds herself. She was born at 30 weeks' gestation.

Which is the best description of her current development?

- A. Fine motor delay
- B. Gross developmental delay
- C. Gross motor delay
- D. Mild developmental delay
- E. Normal development

Correct Answer: C

14. A 37 year old woman who is 10 weeks pregnant has had excessive vomiting for 1 week. The fundal height is consistent with 16 weeks' gestation. Her temperature is 37.2°C, pulse rate 100 bpm and BP 180/110 mmHg.

Which is the most likely diagnosis?

- A. Gastroenteritis
- B. Missed abortion
- C. Molar pregnancy
- D. Pre-eclampsia
- E. Pregnancy-induced hypertension

Correct Answer: C

15. A 29 year old woman has pain and morning stiffness in her finger and wrist joints. This improves during the day and after active movement. She has had recurrent mouth ulcers for the last 2 years. She had an episode of pleuritic chest pain 6 months ago which resolved without seeking help.

Her BP is 128/85 mmHg. She has no warmth or tenderness in her hands.

Urinalysis: protein 1+, blood 1+

Investigations:

Haemoglobin 109 g/L (115–150)

White cell count $3.8 \times 10^9/L$ (4.0–11.0)

Lymphocytes $0.9 \times 10^9/L$ (1.1–3.3)

Platelets $160 \times 10^9/L$ (150–400)

Creatinine 90 $\mu\text{mol/L}$ (60–120)

CRP 21 mg/L (< 5)

Which is the most likely diagnosis?

- A. Behçet's disease
- B. Reactive arthritis
- C. Rheumatoid arthritis
- D. Sjögren's syndrome
- E. Systemic lupus erythematosus

Correct Answer: E

16. A 66 year old man has lethargy, cough and a persistent pain in the right upper quadrant of the abdomen. He has smoked between 15 and 40 cigarettes daily for 50 years.

He has an enlarged liver. Needle biopsy of the liver reveals adenocarcinoma, and immunohistochemistry is positive for the marker thyroid transcription factor-1, indicative of a primary pulmonary tumour.

Which is the most likely route by which this tumour spread to the liver?

- A. Direct infiltration
- B. Haematogenous spread
- C. Lymphatic spread
- D. Pagetoid spread
- E. Transcoelomic spread

Correct Answer: B

17. A 63 year old woman has two days of facial swelling, early morning facial discomfort and fullness. Nine months ago she was treated with chemotherapy and radiotherapy for lung cancer.

Her jugular venous pressure is elevated and non pulsatile. Her face, neck and arms are swollen, and there are prominent veins across her chest.

Which structure is most likely to be occluded?

- A. Axillary vein
- B. Internal jugular vein
- C. Right atrium
- D. Subclavian vein
- E. Superior vena cava

Correct Answer: E

18. A 17 year old attends her GP with her mother. She has had severe headaches, stomach aches and has vomited four times over 2 days.

She was invited to a close friend's birthday party but refused to attend. She is extremely shy and isolated, and has very few friends. She is always worried that others criticise her, is extremely sensitive to any rejection, and is very attached to her mother.

Which personality disorder is she most likely to have?

- A. Avoidant
- B. Dependent
- C. Paranoid
- D. Schizoid
- E. Schizotypal

Correct Answer: A

19. A 45 year old man visits his GP with right knee pain. He has not had any problems with his knee before, but has had previous episodes of a severe pain in his toe and painful swelling of the dorsum of the feet. There is no history of trauma. He drinks 20 pints of beer a week.

His temperature is 37.5°C, and his knee is warm, diffusely tender and very painful to flex.

What is the most likely diagnosis?

- A. Gout
- B. Osteoarthritis
- C. Rheumatoid arthritis
- D. Septic arthritis
- E. Torn meniscal cartilage

Correct Answer: A

20. A 68 year old woman has noticed a lump in her neck for 2 months, but otherwise feels well.

There are small lymph nodes palpable in the cervical, axillary and inguinal regions.

Investigations:

Haemoglobin 124 g/L (115–150)

White cell count $27.2 \times 10^9/L$ (3.8–10.0)

Neutrophils $2.5 \times 10^9/L$ (2.0–7.5)

Lymphocytes $21.6 \times 10^9/L$ (1.1–3.3)

Monocytes $0.9 \times 10^9/L$ (0.2–1.0)

Eosinophils $0.4 \times 10^9/L$ (0–0.4)

Basophils $0.1 \times 10^9/L$ (0–0.1)

Platelets $137 \times 10^9/L$ (150–400)

Blood film: increased lymphocytes with sparse cytoplasm

Which is the most likely diagnosis?

- A. Acute lymphoblastic leukaemia
- B. Chronic lymphocytic leukaemia
- C. Infectious mononucleosis
- D. Myeloma
- E. Non Hodgkin's lymphoma

Correct Answer: B

21. A 15 year old boy has had severe anorexia nervosa for one year. He is not currently acutely physically unwell. His weight is 75% of the expected weight for his height, age and sex.

Which is the most appropriate treatment?

- A. Cognitive-analytic therapy
- B. Cognitive-behaviour therapy
- C. Family therapy
- D. Non-directive counselling
- E. Psychodynamic psychotherapy

Correct Answer: C

22. A randomised controlled trial was designed to compare a new drug with a placebo. There were 120 patients in the treatment group of which 12 patients died within 2 years. There were 240 patients in the control group of which 48 patients died within 2 years.

Which is the number needed to treat to avoid one death within 2 years?

- A. 2
- B. 4
- C. 8
- D. 10
- E. 20

Correct Answer: D

23. A 28 year old woman is elated in mood, has not slept for 7 days and has been attending all-night parties. She is sexually disinhibited and believes that she is a member of the royal family. She was previously fit and well and has no past psychiatric history.

A urine drug screen is negative.

Which is the most appropriate medication?

- A. Diazepam
- B. Lithium carbonate
- C. Olanzapine
- D. Sodium valproate
- E. Zuclopenthixol decanoate

Correct Answer: C

24. A 62 year old woman is seen at home because her legs feel "wobbly", and she has been incontinent of urine once. She has been experiencing increasing pain in her mid back over the previous fortnight. She is being treated for metastatic breast cancer with anastrozole.

There is slight weakness, rated 4/5, in hip flexion and knee extension bilaterally. Plantar reflexes are equivocal and tendon jerks brisk. She is tender over the 10th thoracic vertebra.

Which is the most appropriate next course of action?

- A. Admission to the local hospice
- B. Advise bed rest until pain resolves
- C. Arrange domiciliary physiotherapy
- D. Emergency admission for MR scan of spine
- E. Give analgesia and re-examine her in the morning

Correct Answer: D

25. A 3 year old boy has 6 months of diarrhoea. He has 4-5 watery stools per day that contain visible pieces of sweetcorn and other vegetables. He is thriving and developing well.

Which is the most likely diagnosis?

- A. Coeliac disease
- B. Gastroenteritis
- C. Inflammatory bowel disease
- D. Lactose intolerance
- E. Toddler diarrhoea

Correct Answer: E

26. A mother gives her 6 month old baby girl formula milk for the first time. Within minutes, the baby vomits and develops an erythematous rash over her lips and chin, which takes 1 hour to subside. The following week, the mother drips a couple of drops of formula milk onto the baby's arm. The baby develops an erythematous rash over the arm within 1 minute.

The mother is returning to work and does not wish to continue breastfeeding or expressing milk.

Which is the best management option?

- A. Goat's milk
- B. Hydrolysed formula
- C. Lactose free formula
- D. Latex free teat
- E. Soya milk

Correct Answer: B

27. A 28 year old woman is admitted with a sudden onset of abdominal pain and vaginal bleeding. She is 38 weeks pregnant.

Her pulse rate is 120 bpm and BP 110/80 mmHg. She has a tender abdomen.
The fetal heart rate is 170 bpm.

Which is the most likely diagnosis?

- A. Necrosis of a fibroid
- B. Placenta praevia
- C. Placental abruption
- D. Pre-term labour
- E. Uterine rupture

Correct Answer: C

28. A 52 year old woman has had two days of worsening confusion. She has chronic liver disease secondary to alcohol and has been abstinent for six months. She has had a previous admission due to acute hepatic encephalopathy.

She is disoriented in time and place, and is unable to hold a conversation. Her temperature is 37.1°C, pulse 90 bpm and BP 119/80 mmHg. She has a distended abdomen, widespread spider naevi and a flapping tremor.

She is given intravenous vitamin supplements.

Which is the most appropriate additional management of her acute confusion?

- A. Ciprofloxacin
- B. Furosemide
- C. Lactulose
- D. Lorazepam
- E. Restrict dietary protein intake to 60 g/day

Correct Answer: C

29. A 25 year old nulliparous woman with an uncomplicated pregnancy attends for induction of labour at 41 weeks.

Examination reveals the head is engaged; the cervix is posterior, 2cm long and the os is closed.

Which is the most appropriate method of induction?

- A. Endovaginal prostaglandin gel
- B. Membrane sweep
- C. Oxytocin infusion
- D. Oxytocin infusion and amniotomy
- E. Progesterone suppository

Correct Answer: A

30. A 60 year old man believes that the government has been monitoring him for 10 years, despite him repeatedly writing to the Prime Minister. His beliefs are present whatever his mood, and he has never heard voices when nobody else is around.

Which is the most likely diagnosis?

- A. Anankastic personality disorder
- B. Delusional disorder
- C. Depression with psychosis
- D. Paranoid schizophrenia
- E. Schizoid personality disorder

Correct Answer: B

31. A woman develops a temperature of 38.5°C, 15 minutes after a transfusion of red blood cells.

What is the most likely cause of her high temperature?

- A.** Donor blood not screened for infective agents
- B.** Patient identified incorrectly
- C.** Pre-labelled sample used
- D.** Sample not labelled at the bedside
- E.** Sample not labelled by the person taking the blood

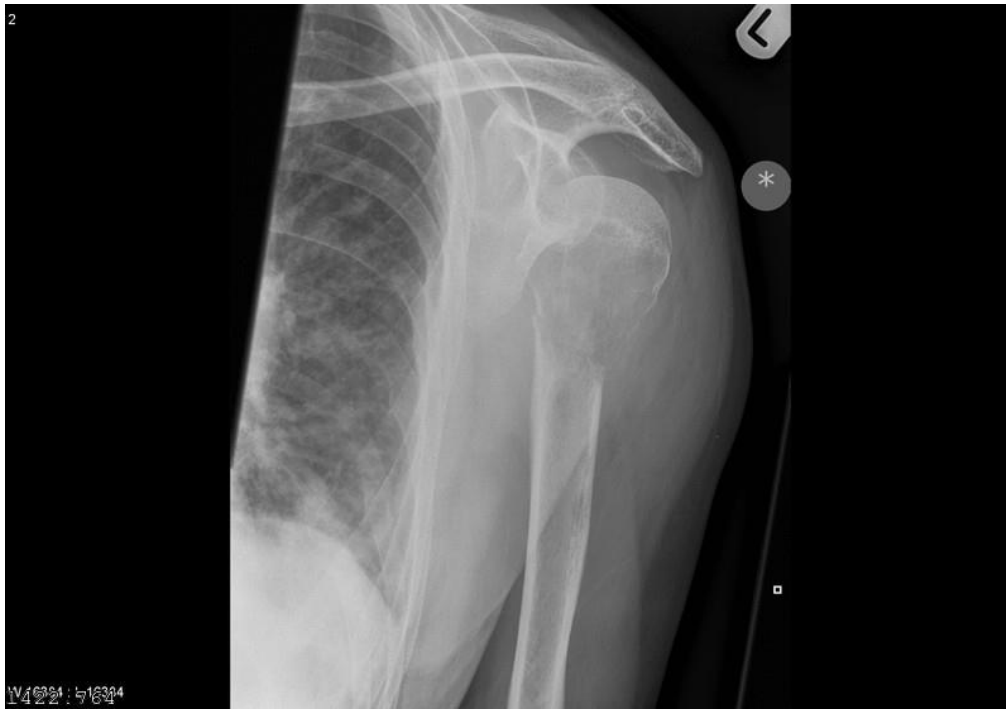Correct Answer: B

32. A 94 year old woman has a deep gnawing pain in her left arm. She has had 10 kg weight loss in the past year.

Her temperature is 37.3°C. She has localised tenderness over the left upper arm.

Investigations:

X-ray left arm (see image).



Which is the most likely cause of her pain?

- A. Metastatic carcinoma
- B. Osteomyelitis
- C. Osteoporosis
- D. Osteosarcoma
- E. Paget's disease

Correct Answer: A

33. A 45 year old man has a 5 month history of chronic sinusitis and unresolving headaches. When he bends forward, purulent fluid pours from his nose.

Which anatomical structure is most likely to be the source of this fluid?

- A. Anterior ethmoid air cells
- B. Frontal sinus
- C. Lacrimal sac
- D. Maxillary sinus
- E. Posterior ethmoid air cells

Correct Answer: D

34. A 6 hour old term baby boy is grunting and cyanosed. He has been struggling to feed.

His temperature is 36.8°C, pulse rate 190 bpm (120-160), respiratory rate 60 breaths per minute (30-60) and oxygen saturation 82% breathing air. His oxygen saturation does not improve significantly breathing high flow oxygen. He has a loud single second heart sound and a systolic murmur.

He is treated with intravenous fluids and antibiotics.

Which is the most appropriate next medication?

- A. Alprostadil
- B. Ibuprofen
- C. Indometacin
- D. Sildenafil
- E. Surfactant

Correct Answer: A

35. A 5 year old girl is brought to her GP with a rash over her arms that has been gradually worsening over the past month. Her mother reports that she seems more tired than usual.

She has a petechial rash over both forearms, with some petechiae over her left anterior chest. She is pale and has hepatosplenomegaly.

Which is the most appropriate management option?

- A. Administer intramuscular benzylpenicillin sodium and send her to hospital in an ambulance
- B. Prescribe a course of prednisolone and review in 3 days
- C. Refer her for a routine appointment in the general paediatric clinic
- D. Refer her urgently to the paediatric assessment unit
- E. Take a full blood count and blood film and see her within 48 h

Correct Answer: D

36. A 62 year old man attends the outpatients clinic with his wife. He has had reduced energy and lack of interest in his work and poor sleep for six weeks. He has lost weight. There is evidence of self-neglect and reduced eye contact. He is known to have benign prostatic enlargement.

What is the single most appropriate drug treatment?

- A. Benzodiazepine
- B. Selective serotonin re-uptake inhibitor
- C. Serotonin noradrenaline re-uptake inhibitor
- D. Tricyclic antidepressant
- E. Z-drug

Correct Answer: B

37. A doctor is approached by their neighbour who is aware that another person on their street has been admitted to the ward the doctor is working on. They wish to know how the patient is doing. The doctor is aware the patient is stable but the prognosis is uncertain.

Which is the most appropriate response by the doctor?

- A. They can confirm they are caring for him and that he is unwell but stable
- B. They can confirm they are caring for him but cannot comment on his condition
- C. They can confirm they are caring for him and that he is making good progress
- D. They cannot confirm they are caring for him but have heard he is unwell but stable
- E. They cannot confirm who is caring for him and cannot comment on his condition

Correct Answer: E

38. A 40 year old woman has had right-sided facial weakness for the past 12 hours.

She has weakness of all of the muscles on the right side of her face. There is no limb weakness and speech is normal. Examination of her ears is normal.

Which is the most appropriate drug treatment?

- A. Aciclovir
- B. Aspirin
- C. Cinnarizine
- D. None
- E. Prednisolone

Correct Answer: E

39. A 35 year old woman with gestational hypertension is induced at 40 weeks. She has a normal vaginal delivery, but following delivery of the placenta she bleeds heavily.

Which is the most appropriate management?

- A. Carboprost
- B. Ergometrine
- C. Oxytocin
- D. Misoprostol
- E. Tranexamic acid

Correct Answer: C

40. A 19 year old man has had two days of a burning sensation when passing urine and a penile discharge. This developed three days after he had unprotected sex with a new female partner.

Which is the most appropriate treatment?

- A. Azithromycin and ceftriaxone
- B. Ciprofloxacin and metronidazole
- C. Fluconazole and penicillin V
- D. Metronidazole and fluconazole
- E. Penicillin V and azithromycin

Correct Answer: A

41. A 9 month old baby boy is brought to his GP with 4 days of coryzal symptoms, intermittent fever, coughing and wheezing. He has been taking smaller feeds for the past 2 days and was unsettled last night. He is alert, there is no rash and he is drooling. He has adequate oral intake. His mother has given him paracetamol suspension.

His temperature is 38.2°C, capillary return 1 second, pulse rate 148 bpm (80-160), respiratory rate 60 breaths per minute (30-60) and oxygen saturation 97% in air. He has widespread wheeze and crackles, and his ears and throat are normal.

Which is the most appropriate next step in management?

- A. Admission to paediatric ward
- B. Prescribe oral doxycycline
- C. Prescribe oral co-amoxiclav
- D. Reassure and give safety netting advice
- E. Give nebulised salbutamol and review

Correct Answer: D

42. A 23 year old woman has barricaded herself with her baby in the bathroom, shouting that it is unsafe to come out because the house is infected. She thinks that someone is trying to kill her and her baby. She is four days post-caesarean section. Her mood has not been low at any stage. She was not on any medication during her pregnancy, but drank 20 units of alcohol a week. Her physical recovery from caesarean section has been uncomplicated. She is orientated in time and place.

Which is the most likely diagnosis?

- A. Alcohol withdrawal
- B. Delirium
- C. Obsessive-compulsive disorder
- D. Post-natal depression
- E. Puerperal psychosis

Correct Answer: E

43. A 20 year old woman seeks contraceptive advice. She had unprotected sexual intercourse four days ago.

Which is the most appropriate method of contraception?

- A. Combined oral contraceptive pill
- B. Copper-containing intrauterine device
- C. Depot progestogen injection
- D. High dose oral progestogen
- E. Intrauterine progestogen system (Mirena coil)

Correct Answer: B

44. A 60 year old man feels tired, but has no specific symptoms. He is a non-smoker and drinks eight units of alcohol per week.

Investigations:

Haemoglobin 120 g/L (130–175)

White cell count $5.8 \times 10^9/L$ (3.0–10.0)

Platelets $170 \times 10^9/L$ (150–400)

MCV 110 fL (80–96)

TSH 2.0 mU/L (0.3–4.2)

Which additional investigation is most likely to help with the diagnosis?

- A. Erythrocyte sedimentation rate
- B. Ferritin
- C. Folate and vitamin B₁₂
- D. Haptoglobin
- E. Protein electrophoresis

Correct Answer: C

45. A 15 year old girl has delayed puberty. She has always been short for her age (height <0.4th centile for age). She has no dysmorphic facial features but does have a webbed neck and widely spaced nipples. She has no breast development, and has not started her periods yet.

Which chromosomal abnormality is most likely to cause her clinical presentation?

- A. 45X0
- B. 47XXX
- C. 47XXY
- D. Trisomy 13
- E. Trisomy 21

Correct Answer: A

46. A 36 year old man is brought to the Emergency Department with a head injury after a fall from 10 metres. He was unconscious for a minute but recovered and seemed fully alert and orientated. Four hours later he becomes drowsy and confused, and then collapses.

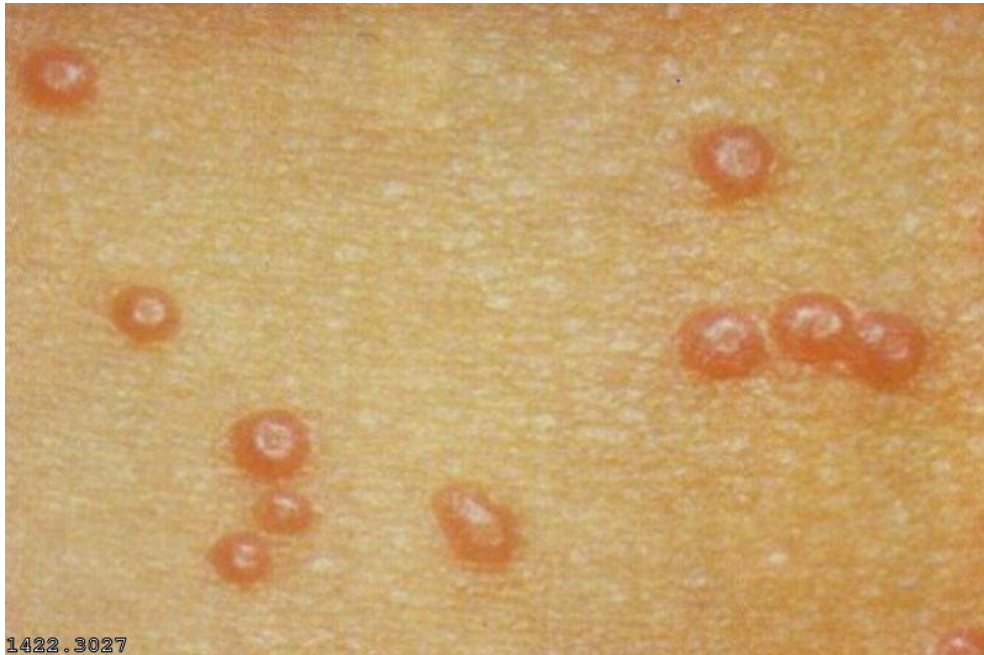
His GCS is 7/15.

Which is the most likely diagnosis?

- A. Cerebral contusions
- B. Compound depressed skull fracture
- C. Diffuse axonal injury
- D. Extradural haematoma
- E. Subarachnoid haemorrhage

Correct Answer: D

47. A 3 year old boy has had multiple skin lesions on his chest wall for 2 weeks (see image). The lesions are not itchy, and he is afebrile and otherwise well.



Which is the most likely diagnosis?

- A. Chickenpox
- B. Discoid eczema
- C. Hand, foot and mouth disease
- D. Molluscum contagiosum
- E. Rubella

Correct Answer: D

48. A 42 year old woman has 6 months of a painful right shoulder. Her pain keeps her awake at night and is worsened by movement. She is otherwise well. There is no history of trauma.

She has pain on shoulder abduction between 80° and 120°. Her shoulder movements are otherwise normal. There is no joint effusion. X-ray of right shoulder is normal.

Which is the most likely diagnosis?

- A. Cervical radiculopathy
- B. Osteoarthritis of glenohumeral joint
- C. Polymyalgia rheumatica
- D. Pseudogout
- E. Subacromial bursitis

Correct Answer: E

49. A 45 year old man has his BMI measured as part of a clinical trial for type 2 diabetes.

Which is the most appropriate classification of data on this parameter?

- A. Categorical
- B. Continuous
- C. Discrete
- D. Nominal
- E. Subjective

Correct Answer: B

50. A 75 year old man with metastatic bowel cancer is dying. He is semi-conscious. He is being treated with morphine and haloperidol via a syringe driver. His breathing is becoming increasingly rattly.

Which is the most appropriate drug management?

- A. Amoxicillin
- B. Furosemide
- C. Hyoscine
- D. Levomepromazine
- E. Midazolam

Correct Answer: C

51. A 67 year old man has had 24 hours of a painful swollen left knee. He went hill walking 3 days ago.

His temperature is 37.6°C, pulse rate 104 bpm and BP 116/80 mmHg. His left knee is red, swollen and hot to touch. He has a reduced range of movement in his knee and is unable to weight bear due to pain.

Investigations:

Haemoglobin 145 g/L (130–175)

White cell count $23.4 \times 10^9/L$ (4.0–11.0)

Platelets $546 \times 10^9/L$ (150–400)

Neutrophils $19.2 \times 10^9/L$ (2.0–7.5)

CRP 122 mg/L (<5)

Which is the most appropriate next investigation?

- A. Aspiration of left knee joint for microscopy and culture
- B. MR imaging of left knee
- C. Serum anti-cyclic citrullinated peptide antibody
- D. Serum uric acid
- E. X-ray of left knee

Correct Answer: A

52. A 36 year old woman and her partner have been trying to conceive for the last 18 months. Neither has ever attained a pregnancy before. Both are medically fit and well and have no surgical history. Her periods are every 38-45 days. Both smoke 5-10 cigarettes per day and drink occasionally at the weekend. Examination is unremarkable in both.

Which is the most likely cause of their inability to conceive?

- A. Abnormal semen
- B. Anovulatory cycles
- C. Parental smoking
- D. Unexplained subfertility
- E. Uterine tube blockage

Correct Answer: B

53. A 45 year old man has a lump in the right side of his neck. He has never smoked and takes no regular medications. Fine needle aspiration of the mass reveals squamous cell carcinoma, and subsequent investigations identify the primary tumour in the right tonsil.

Which virus is associated with this malignancy?

- A. Cytomegalovirus
- B. Epstein–Barr virus
- C. Human immunodeficiency virus
- D. Human papilloma virus
- E. Human T-lymphotropic virus

Correct Answer: D

54. A 78 year old man has worsening breathlessness. He has heart failure that has been worsening progressively over the past 12 months. He has been bed bound for the past 2 weeks. He was recently found to have probable lung carcinoma but was not fit for further investigation.

He is dyspnoeic, cyanosed and confused. His temperature is 36.1°C, pulse rate 100 bpm, BP 92/60 mmHg, respiratory rate 30 breaths per minute and oxygen saturation 88% on 15 L/min via a Venturi mask. He has inspiratory crackles in both bases.

He is treated with intravenous furosemide.

Which additional treatment is most likely to reduce his breathlessness?

- A. Intramuscular haloperidol
- B. Intravenous glyceryl trinitrate
- C. Intravenous morphine
- D. Nasal intermittent positive pressure ventilation
- E. Nebulised salbutamol

Correct Answer: C

55. An 18 year old woman has a sudden sharp stabbing pain in her abdomen, lasting only a few minutes. It is 14 days since her last period started. She indicates that the pain is localised to the left iliac fossa.

A surge in which hormone is most likely to coincide with her pain?

- A. Follicle stimulating hormone
- B. Luteinising hormone
- C. Oestrogen
- D. Progesterone
- E. Prolactin

Correct Answer: B

56. A 72 year old man with lung cancer is admitted to the respiratory ward with recurrent haemoptysis. He is known to the palliative care team and it is felt that he is near the end of his life. He says that he wants to have his terminal care on the respiratory ward because he knows and trusts the nurses. A 'do not attempt resuscitation' form is completed. He subsequently has further haemoptysis and becomes more breathless, so he is treated with an opioid infusion to relieve his dyspnoea. A doctor suggests that the local hospice is better equipped to care for the patient. His son agrees with the doctor, believing that the hospice is "the right place to die".

What should be the most important factor influencing the decision on whether to move him to a hospice?

- A. Consultant's view of patient's best interests
- B. Hospital bed state
- C. Local policy on end of life care
- D. Patient's previous opinion
- E. Son's wishes

Correct Answer: D

57. A 74 year old woman has had left sided headache and discomfort when chewing food for 3 months. She experiences a sensation of pressure and pain in her jaw, even when talking. She has lost 8 kg in weight over the same time period.

Investigations:
CRP 45 mg/L (<5)

Which investigation is most likely to establish the diagnosis?

- A. CT scan of head
- B. Parotid sialogram
- C. Serum anti-neutrophil cytoplasmic antibodies
- D. Temporal artery biopsy
- E. X-ray of temporomandibular joint

Correct Answer: D

58. A group of 75 men and a group of 75 women performed a standardised exercise test and had their pulse rate measured at the end.

The data from the two groups were compared. The data is normally distributed with equal variance.

Which is the most appropriate statistical test to compare these groups?

- A. Analysis of variance
- B. Friedman's test
- C. Mann–Whitney test
- D. Paired Student's t-test
- E. Unpaired Student's t-test

Correct Answer: E

59. A 45 year old man has a tremor that has worsened over several weeks. He has a history of schizophrenia and is taking haloperidol.

He has bilateral tremor and cog-wheel rigidity in his upper limbs.

Which is the most appropriate treatment to manage his symptoms?

- A. Co-beneldopa
- B. Entacapone
- C. Pramipexole
- D. Procyclidine hydrochloride
- E. Selegiline hydrochloride

Correct Answer: D

60. A 30 year old man is unable to straighten his right middle finger after an injury.
He has a flexion deformity of the finger at the distal interphalangeal joint and is unable to actively extend his finger.

Which is the most appropriate management option?

- A. External finger fixation
- B. Finger splint
- C. Internal finger fixation
- D. Reassurance
- E. Steroid injection

Correct Answer: B

61. A previously well 20 year old man has had 2 months of night sweats and 5 kg weight loss.

His temperature is 37.6°C. He has palpable neck lymph nodes and splenomegaly.

Investigations:

CT scan chest, abdomen and pelvis: enlarged mediastinal lymph nodes and splenomegaly

Lymph node biopsy: Hodgkin/Reed-Sternberg (HRS) cells admixed with a polymorphous inflammatory infiltrate

Which is the most appropriate first line treatment?

- A. Chemotherapy
- B. Corticosteroids
- C. Immunotherapy
- D. Radiotherapy
- E. Surgical excision of mediastinal lymph nodes

Correct Answer: A

62. A 72 year old man is admitted with cough, breathlessness and confusion. He has metastatic adenocarcinoma and is being treated with chemotherapy. His wife reports that he has had enough of his treatment and planned to discontinue active treatment.

He is drowsy and unable to answer questions. He has bronchial breathing at the left base. He is given 0.9% sodium chloride and broad spectrum antibiotics intravenously.

Which is the most appropriate way to determine his cardiopulmonary resuscitation status on this admission?

- A.** Admitting team should decide
- B.** Ask an independent advocate to decide
- C.** Ask consultant oncologist to decide
- D.** Ask his wife to decide
- E.** Wait 24 hours to see if patient regains capacity to decide

Correct Answer: A

63. A 36 year old man with type 1 diabetes mellitus has a pilonidal sinus. He takes 14 units long-acting insulin at night, and short-acting insulin three times daily at mealtimes (typically 6-8 units with each meal). He is scheduled for excision of the sinus under general anaesthesia, first on a morning operating list. He is asked to fast from midnight the night before.

His HbA1c is 58 mmol/mol (20-42).

Which is the most appropriate plan for managing his insulin pre-operatively?

- A. Omit evening and morning insulin doses
- B. Start a variable-rate insulin infusion on the morning of surgery
- C. Start a variable-rate insulin infusion the evening before surgery
- D. Take evening and morning insulin doses, as usual
- E. Take usual evening insulin and omit morning insulin

Correct Answer: E

64. A 3 year old girl has had a fever and a runny nose for the past 2 days. She is alert but miserable.

Her temperature is 39.6°C, pulse rate 150 bpm (95-140), BP 105/62 mmHg (90/50-120/180), respiratory rate 36 breaths per minute (20-30) and oxygen saturation 97% in air. She has a red throat and looks flushed with a flat, erythematous rash across her trunk and face that feels rough. There is no rash around her mouth.

Which is the most likely diagnosis?

- A. Kawasaki disease
- B. Measles
- C. Parvovirus infection
- D. Rhinovirus infection
- E. Scarlet fever

Correct Answer: E

65. A one week old fully breastfed baby girl has pale stools in her nappy, with streaks of dark urine (see image). She has lost 8.2% of her birth weight. She was born at term.

She is afebrile. She is alert and has jaundice.



Which is the most appropriate investigation?

- A.** Coombs (direct antiglobulin) test
- B.** Full blood count and film
- C.** Plasma glucose
- D.** Split bilirubin
- E.** Urea and electrolytes

Correct Answer: D

66. A 36 year old woman attends for an asthma review.

She requires a long-acting β -agonist and steroid combination inhaler. The guidelines suggest either a metered dose inhaler or a dry powder. They are the same price. This patient asks which is better for the environment.

Which component of these inhalers has the highest carbon footprint?

- A. Hydrofluorocarbon propellant in the metered dose inhaler
- B. Packaging of the dry powder inhaler
- C. Plastic component of the dry powder inhaler
- D. Plastic component of the metered dose inhaler
- E. Powder component of the dry powder inhaler

Correct Answer: A

67. A 18 year old man is worried about his cancer risk. His paternal grandfather died of colorectal cancer at 42 years of age and his 36 year old father has just been diagnosed with colorectal cancer. The son's colonoscopy shows hundreds of colonic polyps, and biopsies from several of the polyps show adenomatous change with low grade dysplasia.

Which is the most appropriate strategy to prevent colon cancer in this situation?

- A. Daily low dose aspirin
- B. Diet rich in fruit and vegetables
- C. Panproctocolectomy
- D. Annual faecal immunochemical test (FIT)
- E. Annual colonoscopy and biopsy

Correct Answer: C

68. A 21 year old man has a fear of public speaking. He is a student and has to give an oral presentation, and he feels unable to manage this. He fears that he will do something to embarrass himself or even vomit. The thought of giving his presentation gives him palpitations and makes him breathless and dizzy.

He has avoided his tutor for 3 months and has not left his flat for several weeks. He recognises that his fears are irrational but feels overwhelmed.

Which is the most likely diagnosis?

- A. Agoraphobia
- B. Anxious avoidant personality disorder
- C. Emetophobia
- D. Panic disorder
- E. Social phobia

Correct Answer: E

69. A 46 year old man has sudden onset and intense lower back pain. He has no pain or numbness in his buttocks or legs. He is diagnosed with mechanical back pain. He has no drug contra-indications.

Which is the most appropriate initial medication?

- A. Amitriptyline
- B. Fentanyl
- C. Ibuprofen
- D. Paracetamol
- E. Triamcinolone

Correct Answer: C

70. A 56 year old woman has had 2 months of intermittent vertigo, which typically occurs when turning over in bed or looking over her shoulder while driving. Each episode lasts for up to 1 minute. She has no hearing loss, tinnitus or ear pain.

Which test is most likely to confirm the diagnosis?

- A. Audiometry
- B. Carotid doppler ultrasonography
- C. CT scan of head
- D. Dix–Hallpike manoeuvre
- E. MR of internal auditory meatus

Correct Answer: D

71. A 62 year old man is brought to the operating theatre recovery room after a laryngoscopy and vocal cord biopsy. He appears to be conscious, but his breathing is shallow and respiratory rate 28 breaths per minute. His voice is weak and, when the recovery nurse asks him to squeeze her fingers with his hand, the grip is not sustained.

Which drug will reverse these signs?

- A. Doxapram
- B. Glycopyrronium
- C. Naloxone
- D. Neostigmine
- E. Rocuronium

Correct Answer: D

72. A 50 year old woman has broken her right radius after tripping at home. She has been experiencing hot flushes and night sweats for the past six months, with irregular menstruation. She has been taking salbutamol and beclometasone regularly for more than five years to treat asthma. Her fracture heals with no complications.

Which investigation will most effectively evaluate her future risk of fractures?

- A. 99m-technetium bone scintigraphy
- B. Dual energy X-ray absorptiometry
- C. MR scan of spine and hip
- D. Plain X-ray lumbar spine and pelvis
- E. Quantitative CT scan of spine and hip

Correct Answer: B

73. A 72 year old man has had difficulty swallowing solids. He has cancer of the middle third of the oesophagus and hepatic metastases.

Which is the most appropriate initial management of his dysphagia?

- A. Chemotherapy
- B. Excision of tumour
- C. Gastrostomy feeding tube
- D. Oesophageal stent
- E. Radiotherapy

Correct Answer: D

74. A 64 year old man has low thoracic back pain and has been tired for the past 6 weeks. He is a non-smoker. He has hypertension and takes amlodipine.

His urinalysis is normal.

Investigations:

Haemoglobin 81 g/L (135–175)

MCV 82 fL (80–96)

White cell count $4.3 \times 10^9/L$ (3.0–10.0)

Platelets $74 \times 10^9/L$ (150–400)

Creatinine 203 $\mu\text{mol/L}$ (60–120)

Which initial investigation is most likely to help establish the diagnosis?

- A. Anti-neutrophil cytoplasmic antibody
- B. Antinuclear antibody
- C. Complement levels (C3 and C4)
- D. Coagulation screen
- E. Urine and serum protein electrophoresis

Correct Answer: E

75. A 66 year old woman has become forgetful, does not sleep well and has lost her appetite over the last few weeks. She has been getting up early in the morning because she cannot sleep. She feels that she is no longer of any use to the rest of her family.

Mini Mental State Examination is 27/30.

Which is the most likely diagnosis?

- A. Age-associated memory impairment
- B. Alzheimer's disease
- C. Depression
- D. Frontotemporal dementia
- E. Vascular dementia

Correct Answer: C

76. A consultant is looking to find published evidence on reducing the incidence of deep venous thrombosis.

Which type of study would provide the highest quality evidence?

- A.** Case control study
- B.** Case series
- C.** Cohort study
- D.** Meta-analysis of trials
- E.** Randomised controlled trial

Correct Answer: D

77. A 62 year old man has had 3 months of general weakness, fatigue, 10 kg weight loss and mild abdominal discomfort over the right hypochondrium. He was found to have liver cirrhosis 10 years ago and has abstained from alcohol since the diagnosis.

He has a non-tender, fixed hard mass in the right upper quadrant.

Which serum investigation is most appropriate to aid diagnosis?

- A. α -Fetoprotein
- B. β -Human chorionic gonadotropin
- C. CA 125
- D. CA 19-9
- E. Carcinoembryonic antigen

Correct Answer: A

78. A 7 year old boy has intermittent pain in his left groin when playing football and climbing stairs. This has worsened over the past 4 weeks. He has now developed a painless limp.

He has reduced range of movement and pain on internal rotation and abduction.

His temperature is 37.1°C.

Which is the most likely diagnosis?

- A. Osgood–Schlatter disease
- B. Perthes' disease
- C. Septic arthritis
- D. Slipped upper femoral epiphysis
- E. Transient synovitis

Correct Answer: B

79. A 28 year old primigravida attends the antenatal clinic at 35 weeks' gestation. She has 2 weeks of persistent itching of her palms, soles and abdomen. Her pregnancy has been uncomplicated to date, and she is feeling good fetal movements.

She has red scratch marks on her abdomen with no rash.

Which is the most appropriate investigation?

- A. Anti-mitochondrial antibody
- B. Iron studies
- C. Liver function tests
- D. Thyroid function tests
- E. Urea and electrolytes

Correct Answer: C

80. A 23 year old woman commenced chemotherapy for Burkitt's lymphoma yesterday. Since then she has been feeling increasingly nauseated. Urine output has been 40 mL in the last 12 hours.

Her temperature is 36.8°C, pulse rate 96 bpm and BP 112/80 mmHg.

Investigations on admission were normal.

Investigations today:

Potassium 6.2 mmol/L (3.5–5.3)

Urea 9 mmol/L (2.5–7.8)

Creatinine 410 µmol/L (60–120)

Which investigation is most likely to identify the cause of her acute deterioration?

- A. Blood cultures
- B. C reactive protein
- C. Creatine kinase
- D. Phosphate
- E. Urate

Correct Answer: E

81. A 44 year old woman is increasingly hypotensive in the high dependency unit. She was admitted 12 hours earlier with loin pain, dysuria and rigors, and was treated with intravenous broad spectrum antibiotics.

Her temperature is 37.8°C, pulse rate 112 bpm, BP 91/60 mmHg, central venous pressure +12 mmHg and oxygen saturation 95% on 60% oxygen.

Investigations:

Sodium 139 mmol/L (135–146)

Potassium 5.1 mmol/L (3.5-5.3)

Urea 10.3 mmol/L (2.5-7.8)

Creatinine 159 µmol/L (60–120)

She has been treated with 3 L of 0.9% sodium chloride since admission, with a urine output of 400 mL in total and 10–20 mL/hr for the past 4 hours.

Which is the most appropriate next step in management?

- A. Haemofiltration
- B. Intravenous 500 mL gelatin over 30 minutes
- C. Intravenous 500 mL 0.9% sodium chloride over 30 minutes
- D. Intravenous furosemide bolus
- E. Intravenous noradrenaline/norepinephrine infusion

Correct Answer: E

82. A 43 year old man has inoperable cancer of the bowel with hepatic and peritoneal metastases. He has back pain due to tumour infiltration. The pain has been controlled with regular codeine phosphate at maximum dosage. He now has bowel obstruction with vomiting and his pain has recurred because he cannot take oral medication.

Investigations: Creatinine 85 $\mu\text{mol/L}$ (60–120)

Which is the most effective drug to control his pain?

- A. Buprenorphine transcutaneous patch
- B. Codeine phosphate intramuscular injection
- C. Fentanyl transcutaneous patch
- D. Morphine sulfate continuous subcutaneous infusion
- E. Tramadol hydrochloride intramuscular injection

Correct Answer: D

83. A full term newborn boy is discharged home 48 hours after birth. The next day, his 2 year old sibling develops a florid chickenpox rash. His mother has detectable varicella antibodies. The newborn remains clinically well.

Which is the most appropriate management decision?

- A. Admit for observation
- B. Check antibody status for varicella antibodies
- C. No action is necessary
- D. Treat with aciclovir
- E. Treat with zoster immune globulin

Correct Answer: C

84. A 35 year old woman finds a small firm lump on self examination of her breast. It is excised and is a firm, well-circumscribed solid mass, 2.5 cm in diameter.

Histology shows duct-like structures lined by regular, low columnar cells, separated by loose fibrous tissue. The margins are well defined.

Which is the most likely diagnosis?

- A. Carcinoma in situ
- B. Ductal carcinoma
- C. Fibroadenoma
- D. Intraductal papilloma
- E. Paget's disease of the breast

Correct Answer: C

85. A 22 year old woman has intense itching and pain in her right ear that has gradually worsened over several days. She says that her hearing appears to be affected. She is a surfer.

She has debris in the right ear canal, and the tympanic membrane is not visible. There is pain on pulling the pinna.

Which is the most likely diagnosis?

- A. Cholesteatoma
- B. Mastoiditis
- C. Otitis externa
- D. Otitis media
- E. Ruptured tympanic membrane

Correct Answer: C

86. A 35 year old woman has a painful lump in her breast. Her mother had breast cancer at the age of 65 years. She is 32 weeks pregnant with no past medical history. She is not taking any medication. She smokes 5 cigarettes per day.

There is a 2 cm lump in her right breast that is tender on palpation. There is redness of the overlying skin.

Which is the most appropriate management?

- A. Bilateral mammogram
- B. No further investigations until after delivery
- C. Start oral cefalexin
- D. Surgical excision of lump
- E. Triple assessment

Correct Answer: E

87. A 35 year old woman is admitted unconscious to the Emergency Department after being found collapsed outside a pub. There was an empty vodka bottle lying next to her.

Her pulse is 86 bpm, BP 112/62 mmHg, respiratory rate 12 breaths per minute and oxygen saturation is 98% breathing air.

Which is the most important immediate investigation?

- A. Arterial blood gas
- B. Blood alcohol level
- C. Capillary blood glucose
- D. Urea and electrolytes
- E. Urinary drug screen

Correct Answer: C

88. A 28 year old woman has a lobar pneumonia and is treated with intravenous amoxicillin. A few minutes after she is given the antibiotic therapy, she develops an itchy skin eruption and increased breathlessness.

Which is the most likely mechanism of this reaction?

- A. Antibody binding to cell-bound antigen
- B. Complement activation
- C. Delayed-type hypersensitivity
- D. Immediate hypersensitivity
- E. Immune complex hypersensitivity

Correct Answer: D

89. A 39 year old woman has had worsening tiredness for 2 weeks. She was previously well. She is mildly jaundiced. Her pulse rate is 96 bpm and BP 112/76 mmHg.

Investigations:

Haemoglobin 48 g/L (115–150)

White cell count $6.2 \times 10^9/L$ (4.0–11.0)

Platelets $165 \times 10^9/L$ (150–400)

Mean cell volume (MCV) 98 fL (80–96)

Alkaline phosphatase 100 IU/L (25–115)

Aspartate aminotransferase (AST) 27 IU/L (10–40)

Bilirubin (total) 41 $\mu\text{mol/L}$ (< 21)

Lactate dehydrogenase 560 IU/L (70–250)

Blood film: red cell polychromasia, occasional spherocytes, no red cell fragments

Which is the most appropriate diagnostic investigation?

- A. Bone marrow aspiration
- B. Direct antiglobulin test
- C. Serum antinuclear antibody
- D. Serum folate
- E. Serum vitamin B₁₂

Correct Answer: B

90. A 65 year old woman has two episodes of vaginal bleeding. Her last menstrual period was 12 years ago. Abdominal and pelvic examination are normal. Pelvic ultrasound scan shows an endometrial thickness of 10 mm.

Which is the most appropriate next investigation?

- A. CA 125
- B. Cervical cytology
- C. CT scan of pelvis, abdomen and chest
- D. Hysteroscopy and endometrial biopsy
- E. MR scan of pelvis

Correct Answer: D

91. A 25 year old man develops a muscle contraction in his neck causing pain and an involuntary rotation of his neck. He was admitted to the psychiatric unit 24 hours ago with persecutory delusions, agitation, and auditory hallucinations. He has been given risperidone since admission.

Which side effect is he experiencing?

- A. Akathisia
- B. Autonomic instability
- C. Dystonia
- D. Parkinsonism
- E. Tardive dyskinesia

Correct Answer: C

92. An 18 year old woman with sickle cell disease attends the Emergency Department with severe pain in her left leg. She rates her pain score as 8/10.

Her temperature is 36.9°C, pulse rate 110 bpm, BP 120/80 mmHg, respiratory rate 16 breaths per minute and oxygen saturation 96% breathing air.

Investigations:

White cell count $7.1 \times 10^9/L$ (4.0–11.0)

Haemoglobin 71 g/L (115–150)

Platelets $190 \times 10^9/L$ (150–400)

Which is the next management step?

- A. Intravenous co-amoxiclav
- B. Oral prednisolone
- C. Red cell transfusion
- D. Subcutaneous morphine
- E. Treatment dose dalteparin

Correct Answer: D

93. A 79 year old woman has had malaise and pain in the arms and legs for 4 weeks, with morning stiffness that lasts for 3 hours each day. She has difficulty washing and dressing.

She cannot lift her arms above her head due to pain, but there is no objective muscle weakness. She has Heberden's nodes in her hands.

Investigations:

Haemoglobin 112 g/L (115–150)

White cell count $9.8 \times 10^9/L$ (4.0–11.0)

Platelets $365 \times 10^9/L$ (150–400) Mean cell volume (MCV) 89 fL (80–96)

CRP 67 mg/L (<5)

Which is the most likely diagnosis?

- A. Osteoarthritis
- B. Osteomalacia
- C. Polymyalgia rheumatica
- D. Polymyositis
- E. Rheumatoid arthritis

Correct Answer: C

94. A 30 year old woman becomes acutely short of breath. She was admitted to hospital 3 hours ago with an acute exacerbation of asthma. She improved following treatment with oxygen, nebulised salbutamol and oral prednisolone. Her chest X-ray on admission was clear.

Her pulse rate is 122 bpm, BP 88/50 mmHg, respiratory rate 30 breaths per minute and oxygen saturation 88% breathing 40% oxygen via a face mask. She has reduced expansion of the upper left chest. She has mild wheeze throughout the chest with reduced breath sounds over the left apex.

Which is the most likely explanation for her deterioration?

- A. Anaphylaxis
- B. Increasing severity of asthma
- C. Lobar collapse
- D. Pneumothorax
- E. Pulmonary embolus

Correct Answer: D

95. A 40 year old man had a laparotomy for intestinal obstruction 12 hours ago. He has an epidural for analgesia and has been given a 500 mL intravenous crystalloid bolus. He has no pain. He has no pre-existing medical problems. His pulse rate is 120 bpm and BP 80/62 mmHg. He has passed 10 mL of urine in the past 4 hours. He shows no sign of heart failure.

Which is the most appropriate first line of management?

- A. IV diuretic
- B. IV fluid bolus
- C. IV vasoconstrictor
- D. Place bed head down
- E. Stop epidural analgesia

Correct Answer: B

96. A 23 year old man has had joint pains for the last 6 months. He thinks he may have contracted hepatitis B following unprotected sex 6 months ago and is unsure of his hepatitis B vaccination status.

Investigations:

HBsAg –ve

anti-HBc IgG +ve

anti-HBs IgG +ve

What is the best description of his hepatitis B status?

- A.** Acute infection
- B.** Chronic infection
- C.** Immune due to naturally resolved infection
- D.** Immune due to previous vaccination for hepatitis B
- E.** Not infected but susceptible to further infection

Correct Answer: C

97. A 65 year old woman has had headaches for 3 months. She was treated for cancer of the right breast 12 years ago. There is no evidence of local or regional recurrence.

Examination of the central nervous system is normal.

CT scan of brain shows an isolated metastasis with cerebral oedema.

Which is the most appropriate immediate treatment?

- A. Anastrozole
- B. Chemotherapy
- C. Dexamethasone
- D. Radiotherapy
- E. Surgical decompression

Correct Answer: C

98. A 45 year old man has had two hours of colicky left sided abdominal pain radiating to his groin. The pain started abruptly and is associated with nausea and vomiting.

He is restless and writhing in pain. There is tenderness on palpation of the left costovertebral angle. Abdominal examination is normal. Bowel sounds are present but scanty. His urinalysis has 3+.

Which is the most appropriate initial analgesic agent?

- A. Aspirin
- B. Diclofenac
- C. Oxycodone
- D. Paracetamol
- E. Tramadol

Correct Answer: B

99. A 70 year old man has had 1 day of cough and breathlessness. He has a history of COPD and heart failure. His normal exercise tolerance is 100 m. He has had no previous hospital admissions. He has a 35 pack-year smoking history. He is taking lisinopril and uses a tiotropium inhaler.

He is cyanosed and dyspnoeic. His pulse rate is 100 bpm, BP 105/78 mmHg, respiratory rate 30 breaths per minute and oxygen saturation 84% breathing 28% oxygen. He has scattered wheeze and crackles bilaterally. He has been given nebulised salbutamol.

Investigations:

Arterial blood gas on 28% oxygen

pH 7.25 (7.35-7.45)

PO₂ 6.9 kPa (11-15)

PCO₂ 7.8 kPa (4.6-6.4)

Bicarbonate 34 mmol/L (22-30)

Which is the most appropriate next step in management?

- A. Increase oxygen to 40% via a Venturi mask
- B. Intravenous amoxicillin
- C. Intravenous furosemide
- D. Non-invasive ventilation
- E. Reduce oxygen to 2 L/min via a nasal cannula

Correct Answer: D

100. A 2 day old baby boy undergoes his routine neonatal hearing screen. His mother has been deaf since early childhood and has bilateral hearing aids. She asks whether her baby will be deaf.

Which is the most appropriate additional assessment?

- A. Brainstem evoked response test
- B. Cytomegalovirus serology
- C. Distraction testing
- D. MR scan of brain
- E. Weber's test

Correct Answer: A